

Challenges of Acute Lumbar Pain : Clinical Experience of Four Cases of Acute Pyogenic Spondylodiscitis

Haruhiko NAGAMI¹⁾ and Yuzuru MATSUI²⁾

¹⁾Nagami Clinic, Satogata, Kisukicho, Unnan, Shimane 699-1311, Japan

²⁾Department of Orthopedics, Unnan City Hospital², Daitocho, Unnan, Shimane, 699-1221, Japan

(Received December 6, 2011; Accepted January 16, 2012)

Acute pyogenic vertebral spondylodiscitis (APVS) is of special interest to physicians because it often results in acute neurological deterioration and requires a combination of adequate surgical and conservative treatment. The aim of the current study is to evaluate this disease, including its diagnosis and treatment. The subjects of this study were 4 patients with APVS who were treated at the Nagami Clinic in Unnan, Shimane, Japan, from 2000 to 2008. All 4 patients had underlying diseases such as diabetes mellitus and liver cirrhosis. The main causative organism was recognized only in case 3: *Clostridium perfringens* and *Escherichia coli*. Most infections were localized in the lumbar spine, as shown by Magnetic Resonance Imaging (MRI). None of the patients presented with neurological deficits on admission on account of a delay in diagnosis. Clinically, all 4 patients had severe lumbar pain and gait disturbance besides high-grade fever. Of the 4, only one patient with rapidly progressing acute respiratory dysfunction as well as severe septicemia developed multiple organ failure and underwent emergent operation. The other 3 patients were treated with immobilization and intravenous antibiotic drugs. All cases were treated with broad-spectrum antibiotic drugs delivered intravenously for at least 14 days, followed by orally administered antibiotics for more than 14 days. From an etiological viewpoint, it is possible that bacterial infection into the blood flow as a result of surgery resulted in the occurrence of APVS in 2 of the 4 cases. On the other hand, the pathogenesis of the remaining 2 cases was un-

known, but it was speculated that immunoreaction to bacterial invasion was disturbed or feeble in the patients due to their having experienced diabetes mellitus or liver cirrhosis for a long time. Major complications were not recognized, mainly due to long-term antibiotic therapy. APVS is very rare, and it is fatal disease if the diagnosis is delayed. Thus, APVS must be suspected and taken into consideration first if a patient with severe lumbar pain and high-grade fever is encountered. Due to the factors explained above, diagnosing patients with acute lumbar pain presents several challenges.

Key words: Acute pyogenic vertebral spondylodiscitis, Antibiotic treatment, Septicemia

INTRODUCTION

Acute pyogenic vertebral spondylodiscitis (APVS) is a very rare clinical condition [1]. Its incidence, however, appears to be on the rise, which may be attributed to various factors, such as the increase in the elderly population, intravenous drug abuse, and the use of epidural catheters for pain therapy. Other important risk factors are diabetes mellitus and impaired immunocompetence induced by chemotherapy, human immunodeficiency virus infections, or chronic alcoholism [1, 2]. Because APVS often results in acute neurological deterioration and requires a combination of adequate surgical and conservative treatment, it is of special importance to orthopedists. In the past, antibiotic drugs were the standard and only method of treatment for spinal infections. With the advances in modern surgical techniques for spinal instrumentation and fusion, use of these techniques should be reserved for severe cases. Overall, infectious causes of back pain are uncommon. Nevertheless, these conditions must

Correspondence: Haruhiko Nagami, Nagami Clinic 633-1.Satogata Kisukicho, Unnan, Shimane 699-1311, Japan
Tel:+81-854-42-5055
Fax:+81-854-42-5056
E-mail:heratsug@bs.kkm.jp.net

be considered because any delay in diagnosis or treatment may result in many complications. APVS is an infectious etiology of back pain that, when undiagnosed, can result in permanent neurological dysfunction or death. Therefore, it is important to understand that these entities are a likely part of a continuum of infection. Accordingly, we must pay attention to the existence of APVS if we encounter a patient with severe lumbar pain and high-grade fever.

CLINICAL MATERIAL

During the 8-year period between 2000 and 2008, 4 patients (3 men and 1 woman) ranging in age from 59 to 74 years (median age, 66.8 years) visited at my facility with clinical signs of APVS. After diagnosis of APVS for the 4 cases at my facility, all patients were transferred to another hospital for treatment of this disease. At admission, the lumbar vertebra and discs of all patients were precisely examined by conventional spine X-ray films, Magnetic Resonance Imaging (MRI), and Computed Tomography (CT) scanning, and laboratory data of all patients were analyzed. The neurological and neuroimaging outcome was assessed at admission and at the time of discharge. After discharge, all patients were followed up for approximately 3

years. Additionally, all patients were required to answer a structured medical questionnaire (intensity of pain, other complications, and activities of daily living). One patient with a completely or rapidly progressing inflammation, case 3, underwent emergent surgery. A surgical procedure was performed by the dorsal approach in a one-stage operation. The other three patients with minor or no deficits or a stable neurological condition were treated with immobilization and intravenous antibiotic drugs for up to 14 days. Antibiotic treatment included the use of intravenous broad-spectrum drugs for at least 14 days followed by oral antibiotics for more than 14 days, and therapy was continued if inflammation-specific laboratory values [C-reactive protein and white blood cell count] remained outside of the normal range. After recovery of APVS, all patients received specialized rehabilitation training. Precise information regarding the present 4 cases is given in Table 1.

CLINICAL CASES

Case 1: A 68-year-old man visited at my facility with the chief complaint of left back pain about ten years and six months ago. Upon arrival at my facility, apart from left-sided low back pain radiating to the ipsilateral foot, he complained of mild-grade

Table 1: The precise demonstration of the present 4 cases (age, sex, chief complaint, complication, treatment, admission days and prognosis)

	age	sex	complication	clinical symptom	treatment	admission	result
CASE1	68	male	HT DM (HbA1C 6.5%)	high grade fever sever lumbago gait disturbance	conservative therapy	85days	alive
CASE2	66	male	HT LC (HbA1C 6.3%)	high grade fever sever lumbago gait disturbance	conservative therapy	68days	alive
CASE3	59	female	HT DM (HbA1C 6.9%)	high grade fever respiratory dysfunction septic shock	surgical treatment	196days	alive
CASE4	74	male	HT AAA	high grade fever sever lumbago	conservative therapy	46days	alive

HT:hypertension, DM:diabetes mellitus, LC:liver cirrhosis, PA:perianal abscess, AAA:abdominal aortic aneurysm

fever and difficulty walking. Furthermore, he was experiencing loss of appetite. At my facility, plain films of thoracolumbar spine revealed lumbar scoliosis, convexity to the right, and no evidence of osteolytic or osteoblastic lesion. He received frequent local injections of 1% xylocaine to relieve the pain around the area of lumbar pain and, additionally, oral administration of non-steroidal inflammatory drugs (NSAIDs). His vital signs after 14th days at my facility were abnormal: body temperature, 38.7°C; pulse rate, 86 beats/minute; respiratory rate, 20 breaths/minute; blood pressure, 113/67 mmHg. On physical examination, he looked sick, and marked tenderness at both sides of the lower back was observed. The laboratory investigations demonstrated leucocytosis and mild anemia (white blood count of $18.4 \times 10^3/\text{ml}$ and hematocrit of 32.4%). His liver function test was within normal limits, but his renal function test was not. The fasting blood sugar was elevated to 275 mg/dl. The HbA_{1c} value was 6.5%. His case was complicated by moderate diabetes mellitus and hypertension, for which he was administered drugs. However, his lumbar pain gradually worsened, and he became unable to walk for even a ten meters. The cause of the walking difficulty and severe lumbar pain was not clarified at my facility. Then, he was sent to Unnan Public Hospital for the examination and treatment of his symptoms. Immediately after admission at the hospital, an MRI was performed, which demonstrated L3/L4-level APVS (Fig. 1). In the hemoculture, the pathogen causing the disease was not identified. To this patient, penicillin G and clindamycin were administered intravenously for 14 days after admission and orally for 2 weeks. During treatment, the patient became afebrile and looked well. His general condition gradually improved. However, on the 34th day after admission, he suddenly vomited massive amounts of blood. Emergent uppergastroscopy was performed, demonstrating a giant gastric ulcer at the middle portion of the gastric body. The volume of blood vomited by the patient was massive; thus, a blood transfusion was performed (approximately 1,600 ml). Subsequently, his gastric ulcer lesion completely healed by administration of a proton pump inhibitor. After the treatment for APVS, the patient's condition improved, and he was transferred

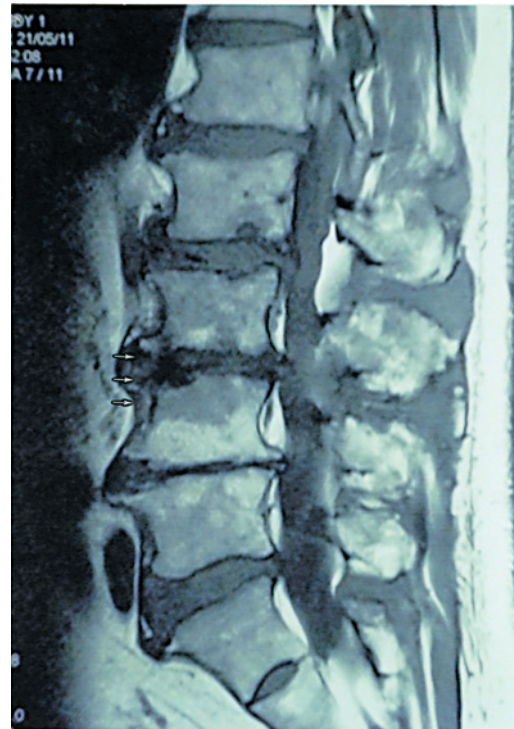


Fig 1: MR imaging (T₁-weighted MR images) showed L3/L4-level APVS (CASE 1)(→)

to a rehabilitation unit. Through rehabilitation, he was able to walk longer distances without assistance. He was discharged at day 75 after admission without morbidity. However, he continued to suffer from mild lumbar pain and received NSAIDs for treatment for about three years after discharge.

Case 2 : A 75-year-old man visited at my facility with the chief complaint of right back pain about eight years and two months ago. He was treated by administration of NSAIDs and microwaves, but his lumbar pain did not improve. On the contrary, his pain worsened day by day, and, at 10 days after treatment, he could not walk without assistance. His vital signs at 14 days after visiting at my facility were abnormal: body temperature, 38.7°C; pulse rate, 86 beats/minute; respiratory rate, 20 breaths/minute; blood pressure, 113/67 mmHg. On physical examination, marked tenderness at both sides of the lower back was observed. The laboratory investigations demonstrated marked leucocytosis and mild anemia (white blood count of $20.4 \times 10^3/\text{ml}$ and hematocrit of 27.4%). The liver function test and renal function test were outside of the normal limits. The pre-meal blood sugar was elevated to 245 mg/dl. The HbA_{1c} value was 6.3 %. His case was

complicated with moderate diabetes mellitus and liver cirrhosis, for which the patient was administered drugs. The cause of difficulty in walking and severe lumbar pain was not clarified at my facility. Thus, he was sent to Unnan Public Hospital for the examination and treatment of his symptoms. Immediately after admission to that hospital, MRI was performed, demonstrating L5/S1-level APVS (Fig. 2). In the hemoculture, the pathogen causing the disease was not identified. To this patient, flomoxef sodium and penicillin G were administered intravenously for 10 days after admission and orally for 2 weeks. During treatment, the patient became afebrile and looked well. His general condition gradually improved. However, at the 48th day after admission, his liver function dramatically worsened, and he fell into acute hepatic failure. Immediately, plasmapheresis was performed, and intravenous infusion of prostaglandin E was given in order to increase the hepatic blood flow. Fortunately, he recovered from hepatic failure and was discharged at 78 days after admission. During his recovery, his condition improved, and he was transferred to a rehabilitation unit. Through rehabilitation, he was able to walk longer distances without assistance. He suffered

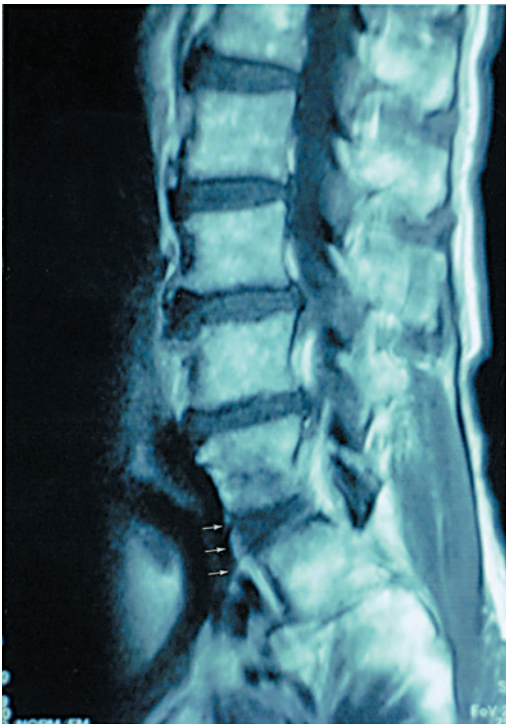

Fig 2 : MR imaging (T₁-weighted MR images) showed L5/S1-level APVS (CASE 2) (→).

from moderate lumbar pain after discharge, and his walk was slightly disturbed. His quality of life was not sufficient. To correct his mild lumbar pain, he also received NSAIDs for about two years. Finally, he died of acute hepatic failure and massive bleeding of the esophageal varix after two years.

Case 3: A 56-year-old woman suffered from a perianal abscess for 15 days. She visited at my facility for treatment of the perianal abscess on account of her severe pain about eleven years and five months ago. Immediately, incision and drainage of the abscess were performed under local anesthesia at my facility. After this operation, her perianal pain progressively decreased, but, 10 days after the drainage operation, she noted difficulty walking and weakness of the legs. On the 17th day after the drainage operation, progressive weakness of the legs developed within two hours, and she complained of high-grade fever and severe lumbar pain as well as gait disturbance. She was suspected of having APVS and sent to a nearby hospital. MRI and CT scanning showed an abscess with gas formation in front of the L4/L5 lumbar vertebrae (Fig 3, Fig 4). Suddenly, her general condition rapidly worsened, with complications of acute respiratory distress syndrome and septicemia. Upon falling into a severe shock state, she was sent to Tottori University Hospital. On arrival at the department of Orthopedics at Tottori University Hospital, her body temperature was 39.8°C, her white blood cell count, 21, 600 cells/mm³, and her CRP, 28.9 mg/L. Emergent MRI and CT scanning were performed, which revealed a ventrally located fluid collection with gas formation extending from approximately L3/L4 and a spondylodiscitis at the L3 level. Emergent operation represented by ventral dissection at L3 was performed, and, at the same time, a ventral single fusion with placement of a carbon cage and a ventral plate was conducted. Operative smears were positive for *Clostridium perfringens* and *Escherichia coli*. After operation, this patient fell into septic shock and multiple organ failure; thus, she stayed in the intensive care unit for 24 days. Postoperatively, the patient underwent intravenous administration of antibiotic drugs (clindamycin, ceftriaxone, and gentamicin) for 14 days and oral administration of antibiotics (clindamycin) for 3 weeks. At six months

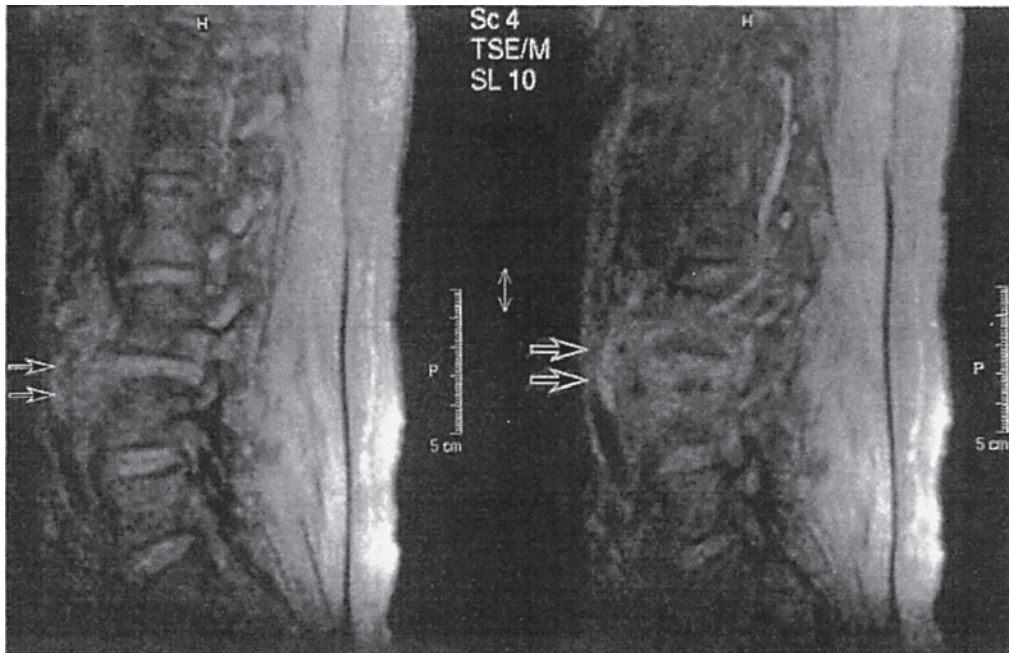


Fig 3: MR imaging (T₁-weighted MR images) showed an acute abscess formation with gas formation in front of the L3/4 vertebral bone(→). (CASE 3)

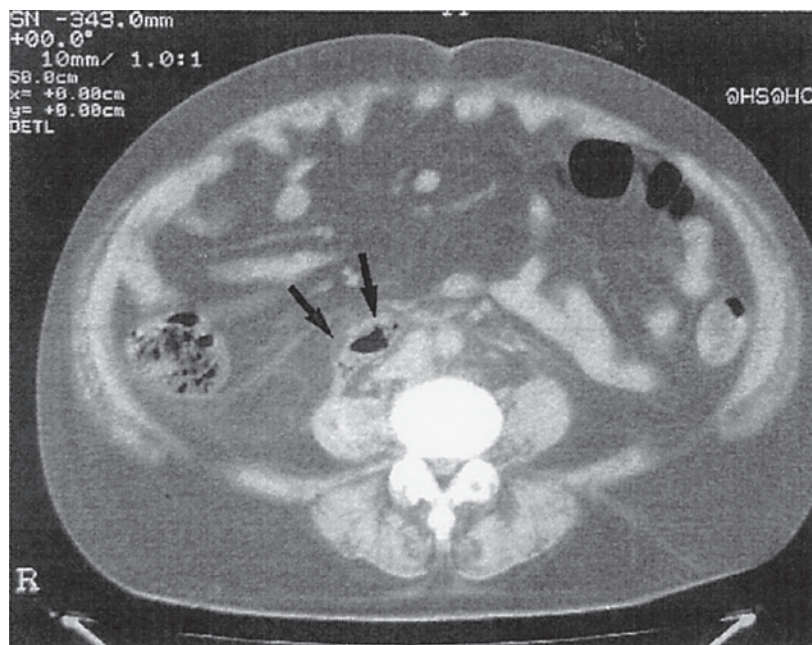


Fig 4: CT scanning showed that abscess with gas formation in front of the L3 vertebral bone(→) (CASE 3)

after surgery, she was neurologically intact, and 8 months after surgery, she was able to resume her farming activities. Follow-up MRI and plain x-ray films demonstrated good results. However, she continued to suffer from mild low back pain and had to take NSAIDs daily to relieve it about for seven years. Moreover, she had abdominal hernia-

tion because of abdominal muscle infection due to the emergent operation.

Case 4: A 74-year-old man visited at my facility with the chief complaint of abdominal distention. At my clinic, abdominal ultrasonography (AUS) showed a pulsatile abdominal tumor. AUS demonstrated an abdominal aortic aneurysm measuring

6.6×5.5cm. The patient was sent to the Shimane Prefectural Central Hospital to receive a vascular operation. Replacement of an abdominal aortic aneurysm with a Y-shaped prosthesis was performed about five years and six months ago. The patient's postoperative course was good. However, on postoperative 18th day, his intestinal bowel was obstructed by operative adhesion; as a result, his oral intake of foods was discontinued, and he received intravenous administration of hyperalimentation. After approximately one month, he recovered from the intestinal obstruction and was permitted to take foods orally. On the 55th day after admission, he was discharged from the hospital. However, just after discharge, he visited at my facility with the chief complaint of high-grade fever, severe lumbar pain, and gait disturbance. He was suspected of having APVS and sent to Shimane Prefectural Hospital for treatment. Upon admission, X-ray films, MRI, and CT scanning revealed findings consistent with APVS at L4/L5 (Fig. 5). His body temperature at admission was 38.7°C, his white blood cell count, 29,700 cells/mm³, and his CRP value, 21.5 mg/L. Initially, the patient received intravenous antibiotic medications for 14 days (ciprofloxacin, dicloxacillin, and clindamycin). Eighteen days after treatment, the

patient's condition improved, and he was transferred to a rehabilitation unit. After two months, he was discharged from the hospital and was able to walk longer distances without assistance. However, because he continued to suffer from mild lumbar pain, he also received NSAIDs for five years.

DISCUSSION

APVS is a disease that mainly affects the older population [1, 2, 3] or patients with known risk factors [1-7]. This was also true for the present patients, most of whom presented with at least one risk factor, such as diabetes mellitus or chronic alcohol or nicotine abuse or excess weight with a body mass index of more than 30 kg/m². Of the present 4 patients, 3 patients had diabetes mellitus as a risk factor. Furthermore, it was strongly suspected that APVS in cases 3 and 4 was the result of hematogenous spread from a distant focus via blood flow of the first operation and bacterial translocation due to intestinal bowel obstruction, respectively. Especially in case 3, after drainage of the perianal abscess, anaerobic bacteria invaded the blood flow and reached the L3/L4-level disc, eventually forming an abscess with gas formation. This type of inflammation was classified as Stage V by Griffiths' classification [8] of APVS. The treatment of case 3 was only a selected surgical procedure because the patient had already fallen into septic shock and suffered from multiple organ failure. Thus, her hospitalization, including intensive care and antibiotic therapy, was considerably long. Fortunately, she recovered completely both by surgical procedure and postoperative administration of antibiotics. On the contrary, in case 4, the patient suffered from postoperative intestinal bowel obstruction after surgery of an abdominal aortic aneurysm. It is possible that, because of dilatation of the small intestine by intestinal obstruction for a long time, bacterial invasion into the blood flow easily occurred by bacterial translocation in the bowel. Then, this bacterial invasion by bacterial translocation might have induced the occurrence of APVS. MRI showed that this inflammation was classified as Class III by Griffiths' classification of APVS [8]. Meanwhile, the exact mechanism of cases 1

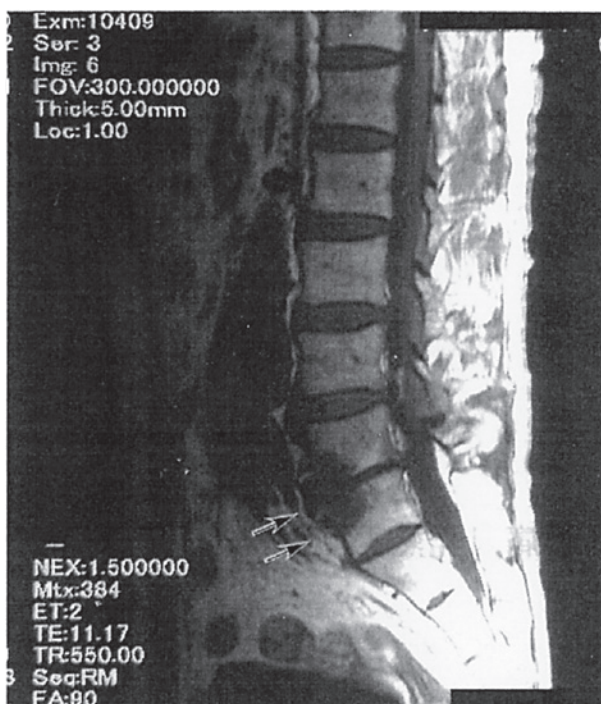


Fig 5: MR imaging showed a pyogenic discitis and osteomyelitis at L4/5 vertebral bone(→).(CASE4)

and 2 was not clear. However, those two patients had suffered from diabetes mellitus for a long time, and their blood sugar control was not sufficient represented by the HbA_{1c} value. In case 2, liver cirrhosis in addition to diabetes mellitus might have induced APVS. Because of these diseases, immunoreaction was speculated to be possibly weakened, and hematogenous spread of bacteria from a distant focus via blood flow might have easily happened. From these facts, in cases 1, 2, and 3, immunoreactivity of the host against bacteria invasion might have been weakened.

The typical patient with APVS presents with acute pain at the site of infection combined with fever. Low-back pain or sciatica is also a common symptom and has been reported in the literature [9, 10]. Severe back pain due to APVS typically presents in an indolent fashion over a period of weeks or months. The location of pain can be anywhere along the spine, although the thoracic and lumbar areas are more commonly involved. Physical examination usually reveals tenderness or percussion of the spinous process of the involved vertebral body. Although a thorough neurological examination is necessary, significant deficits are found in less than 20% of patients who have APVS [11]. However, patients' temperature must be interpreted with caution. It is well known that patients with APVS are frequently afebrile. Thus, the lack of fever is insufficient evidence to rule out the diagnosis. A history of recent febrile episodes was present in all 4 patients visiting at my facility, and laboratory examinations specific for infections showed abnormal values in all of the patients (CRP and white blood cell count). According to the present study and most other authors, diagnosis of APVS is often delayed [1-6]. In my experience, diagnosis of APVS in cases 1 and 2 was delayed because I had never experienced such a case of APVS. On account of delayed diagnosis of APVS, the infection spreads, leading to epidural abscess formation and compromising the spinal cord, with subsequent neurological deterioration. The frequency of neurological deficits on admission varies [1, 12] but may be as high as 60% [13].

The major diagnostic tool in the present study was MRI in all patients, and this modality has

proven to be the diagnostic tool of choice [3-6, 14]. It has been reported that MRI is as sensitive, specific, and accurate as the combination of CT scanning with nuclear medicine studies [15]. In APVS, the classic findings on T₁-weighted MRI are low-signal areas of the vertebra and destruction of the cortical margins of the vertebra. A high signal in affected areas of the vertebra and the adjacent discs is typical on T₁-weighted MRI.

The least invasive method available to obtain a bacteriological diagnosis is a blood culture. These are positive in only 35% of cases [9, 16]. Some authors favor needle biopsy sampling of the affected vertebrae to establish the diagnosis [10], although such procedure is thought to be difficult. In the largest study so far, needle biopsy procedures led to identification of the causative organism in only 53% of cases [1, 10]. Needle biopsy sampling followed by conservative treatment may be an option in early cases of spinal infection [1]. In the present analysis, tissue cultures were obtained in only one patient (case 3), and, in the other three patients (cases 2, 3, and 4), isolation of bacterial cultures was not successfully done because abscess of vertebral discitis inflammation was not obtained by fine needle biopsy. Furthermore, the blood culture was negative in those three patients. This low rate may be the result of antibiotic therapy or long transportation time interfering with the growth of anaerobic bacteria. The most commonly isolated organism in APVS is said to be *Staphylococcus aureus*, which is found in 30% of patients [12]. This coincides with the current literature, in which *Staphylococcus aureus* accounts for 42 to 84% of all spinal infections [10], followed by gram-negative organisms and anaerobic bacteria [1]. Depending on the patient population, other organisms, including gram-negative bacilli such as *Pseudomonas aeruginosa*, various *Candida species*, *Salmonella*, and *Mycobacterium tuberculosis*, have been reported [11]. More commonly, these organisms cause APVS as a result of hematogenous spread from a distant focus. Other, less common sources of infection are contiguous spread from an adjacent infection and direct inoculation from a medical procedure [11]. In the present study, anaerobic bacteria represented by *Clostridium perfringens* were identified as the

reason of APVS in case 3. However, in the other three cases, the bacterium causing APVS was not identified because the patients had recovered from APVS by administration of antibiotic drugs alone without operation. Moreover, fine needle biopsy was not performed because the patients did not consent to the procedure. Considering that the patients recovered by antibiotic drug administration alone, the bacteria causing APVS were probably gram-positive feeble bacteria, such as *Staphylococcus aureus*.

Surgeons are generally reluctant to implant foreign material in infected parts of the body. Thus, there are only limited studies in which instrumentation is used to treat spinal infections. With improved surgical techniques, the use of new broad-spectrum antibiotic medications, and the development of better materials for spondylodesis, numerous authors nowadays favor a primary surgical approach to treat spinal infections [5, 6, 17, 18]. The main advantage of the surgical approach is that it addresses all aspects of the disease: *débridement* of the infected tissue; identification of the causative organism, enabling specific antibiotic therapy; correction of the eventually deformed spine; and decompression of the spinal cord. Surgical treatment also allows immediate mobilization, thus avoiding the side effects of long-term bed rest, such as deep venous thrombosis. The ideal treatment program advocated by me is shown in Fig. 6. Whether an anterior or a posterior approach should be used is still a matter of discussion [17]. It is believed that gen-

eral statements on whether either of these approaches is superior cannot be made: performance of surgery for spinal infections has to be determined on an individual basis. Most patients improved significantly after surgery; besides improvement of their general condition (fever and infection parameters), neurological recovery was observed in most of them [19]. In the present study, adverse effects, mainly due to long-term antibiotic therapy, were fortunately not recognized in any of the 4 patients.

APVS is of special interest because it often results in acute neurological deterioration and requires a combination of adequate surgical and conservative treatment. Its pathogenesis may have close connection with various risk factors, such as diabetes mellitus, impaired immunocompetence (chemotherapy, human immunodeficiency), virus infections, or chronic alcoholism in the elderly population. Because APVS often results in acute neurological deterioration or severe inflammation (sepsis) and requires a combination of adequate surgical and conservative treatment, it is of special importance to suspect APVS when a patient with severe pain, high-grade fever, and gait disturbance is encountered. However, we must take into consideration with caution that the pain of the patients suffering from APVS was not rapidly or completely corrected by surgical treatment or conservative treatment.

REFERENCES

- 1) Levi ADO and Sonntag VKH (1999) Pyogenic vertebral osteomyelitis. In: *Infections in Neurological Surgery: Diagnosis and Management*. (Osenbach RK, Zeidman SM eds). pp 257-263, Lippincott-Raven, Philadelphia.
- 2) Sascha M, Michael S, Steffen S and Jürgen P (2004) Nonspecific pyogenic spondylodiscitis : clinical manifestations, surgical treatment , and outcome in 24 patients. *Neurosurg Focus* 17: 1-7.
- 3) Krogsgaard MR, Wagn P and Bengtsson J (1998) Epidemiology of acute vertebral osteomyelitis in Denmark: 137 cases in Denmark 1978-1982, compared to cases reported to the National Patient Register 1991-1993. *Acta Orthop Scand* 69: 513-517.
- 4) Khan 1A, Vaccaro AR and Zlotolow DA (1999)

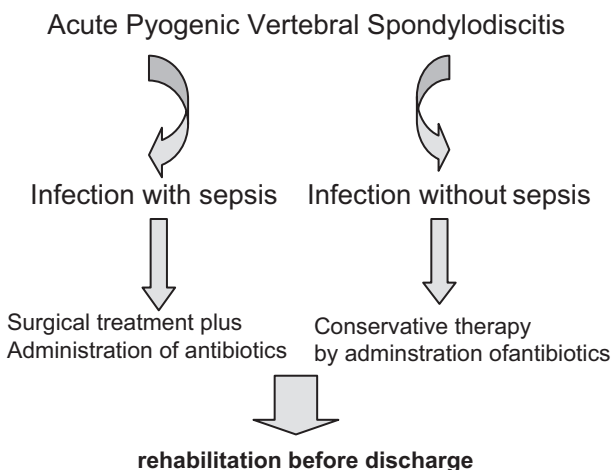


Fig 6: Ideal treatment program according to the severity of APVS

- Management of vertebral diskitis and osteomyelitis. *Orthopedics* 22: 758-765.
- 5) Klockner C and Valencia R (2003) Sagittal alignment after anterior debridement and fusion with or without additional posterior instrumentation in the treatment of pyogenic and tuberculous spondylodiscitis. *Spine* 28: 1036-1042.
 - 6) Linhardt O, Kruger A and Krodel A (2004) First results of anterior versus posterior instrumentation-fusion in the treatment of spondylodiscitis. *Z Orthop Ihre Grenzgeb* 142: 73-78.
 - 7) Castilla JM, Martin V and Rodriguez-Salazar A (2002) Surgical treatment of patients with spinal infection. *Neurocirugia* 13: 101-109.
 - 8) Griffiths HED and Jones DM (1971) Pyogenic infection of the spine. *J Bone Joint Surg* 53-B: 383-391.
 - 9) Osenbach RK, Hitchon PW and Menezes AH (1990) Diagnosis and management of pyogenic vertebral osteomyelitis in adults. *Surg Neurol* 33: 266-275.
 - 10) Phadke DM, Lucas DR and Madan S (2001) Fine-needle aspiration biopsy of vertebral and intervertebral disc lesions: specimen adequacy, diagnostic utility, and pitfalls. *Arch Pathol Lab Med* 125: 1463-1468.
 - 11) Calder KK and Severyn FA (2003) Surgical emergencies in the intravenous drug user. *Emerg Med Clin North Am* 21: 1089-1116.
 - 12) Lew DP and Waldvogel FA (2004) Osteomyelitis. *Lancet* 364: 369-385.
 - 13) Nolla JM, Ariza J and Gomez-Vaquero C (2002) Spontaneous pyogenic vertebral osteomyelitis in nondrug users. *Semin Arthritis Rheum* 31: 271-278.
 - 14) Raith SA, Neff U and Schneider O (1996) Neurosurgical management of thoracic and lumbar vertebral osteomyelitis and discitis in adults; a review of 43 consecutive surgically treated patients. *Neurosurgery* 38: 926-933.
 - 15) Tali ET (2004) Spinal infections. *Eur J Radiol* 50: 120-133.
 - 16) Hitchon PW, Osenbach RK and Yuh WT (1992) Spinal infections. *Spine* 25: 1668-1679.
 - 17) Przybylski GJ and Sharan AD (2001) Single-stage autogenous bone grafting and internal fixation in the surgical management of pyogenic discitis and vertebral osteomyelitis. *J Neurosurg Spine* 94: 1-7.
 - 18) Schinkel C, Gottwald M and Andress HJ (2003) Surgical treatment of spondylodiscitis. *Surg Infect* 4: 378-391.
 - 19) Faraj AA and Webb JK (2000) Spinal instrumentation for primary pyogenic infection report of 31 patients. *Acts Orthop Belg* 66:242-247.

