

# A Case With Dermatomyositis-related Swallowing Disorder Treated by Intermittent Oro-Esophageal Tube Feeding

Takeshi IEDA, Akiko ISHIDA, Kimi YONEHARA, Taku TADENUMA and Sokichi MANIWA

Division of Rehabilitation, Shimane University Hospital, Izumo 693-8501, Japan

(Received August 28, 2009; Accepted October 26, 2009)

A seventy-year-old man was admitted to our hospital for treatment of dermatomyositis. The patient complained of progressive dysphagia symptom after admission and prednisolone therapy was administered. Videofluoroscopic examination of the patient swallowing showed poor laryngeal excursion, delayed swallow reflex, decreased pharyngeal peristalsis and impaired laryngeal closure. Thus, swallowing therapy, including muscle exercises around the neck and the tongue, were started immediately. In addition, intermittent oro-esophageal tubing technique (IOE) was introduced for improved swallowing function, since IOE is easily performed in patients without gag reflex induced by pharyngeal stimulation. The patient mastered the self-tubing technique within a few days and continued IOE. The patient's swallowing function gradually improved and he could intake food at 13 weeks after the introduction of IOE therapy. IOE is effective to improve nutrition status and swallowing function for patients with swallowing dysfunction caused by the abnormalities of pharyngeal stage in deglutition.

Key words: dysphagia, dermatomyositis, swallowing therapy, intermittent oro- esophageal tube feeding

## INTRODUCTION

Swallowing dysfunction is a common symptom in patients with dermatomyositis and an incidence rate of 35% was reported by Hoshino *et al.* (1). Swallowing disorder causes patients to lose the pleasure of eating and exposes them to life-threatening complications, such as aspiration pneumonia and malnutrition. Here, we report a case with dermatomyositis-related

swallowing dysfunction, which was treated effectively using swallowing therapy including oro-esophageal tubing technique (2).

## CASE REPORT

A seventy-year-old man with erythema over his whole body and diffuse muscle pain was admitted to our hospital. This patient had a history of gastric and rectal cancer, and was suffering from diabetes mellitus. He was diagnosed as dermatomyositis and daily therapy of 60mg of prednisolone was administered soon after admission. The patient's muscular strength of trunk and extremities was normal and swallowing dysfunction was not identified at admission. However, the patient complained of dysphagia and loss of pharyngeal sensation while swallowing at 3 weeks after admission and his dysphagia worsened even after additional gamma-globulin therapy. His dysphagia grade at this time was 2 according to Fujishima's grading system (3), in which normal function is grade 10 and the worst function is grade 1. Thus, he consulted a speech-language-hearing therapist at 5 weeks after admission. Physical examination revealed that sensation of the posterior wall of his pharynx was diminished and gag reflex was not induced by pharynx stimulation, although dysarthria was not observed. Thus, direct and indirect swallowing therapies were immediately started. Eating was prohibited and total parenteral nutrition (TPN) was started at 6 weeks after admission since the degree of inflammation was suddenly aggravated and the patient could not swallow at this time. General erythema disappeared and the serum level of creatinin kinase (CK) was normalized at 2 weeks after the introduction of daily therapy of 80 mg of prednisolone. However, muscle atrophy and dysphagia were not improved. Therefore, physical therapy was also applied after normalization of the CK serum level (Fig. 1).

Repetitive saliva swallowing test (RSST) (4) (twice

Correspondence: Takeshi IEDA, MSc., Speech-Language-Hearing Therapist, Division of Rehabilitation, Shimane University Hospital, 89-1, Enya-cho, Izumo 693-8501, Japan  
Tel: +81-853-20-2457  
Fax: +81-853-20-2305  
E-mail: osukun@med.shimane-u.ac.jp

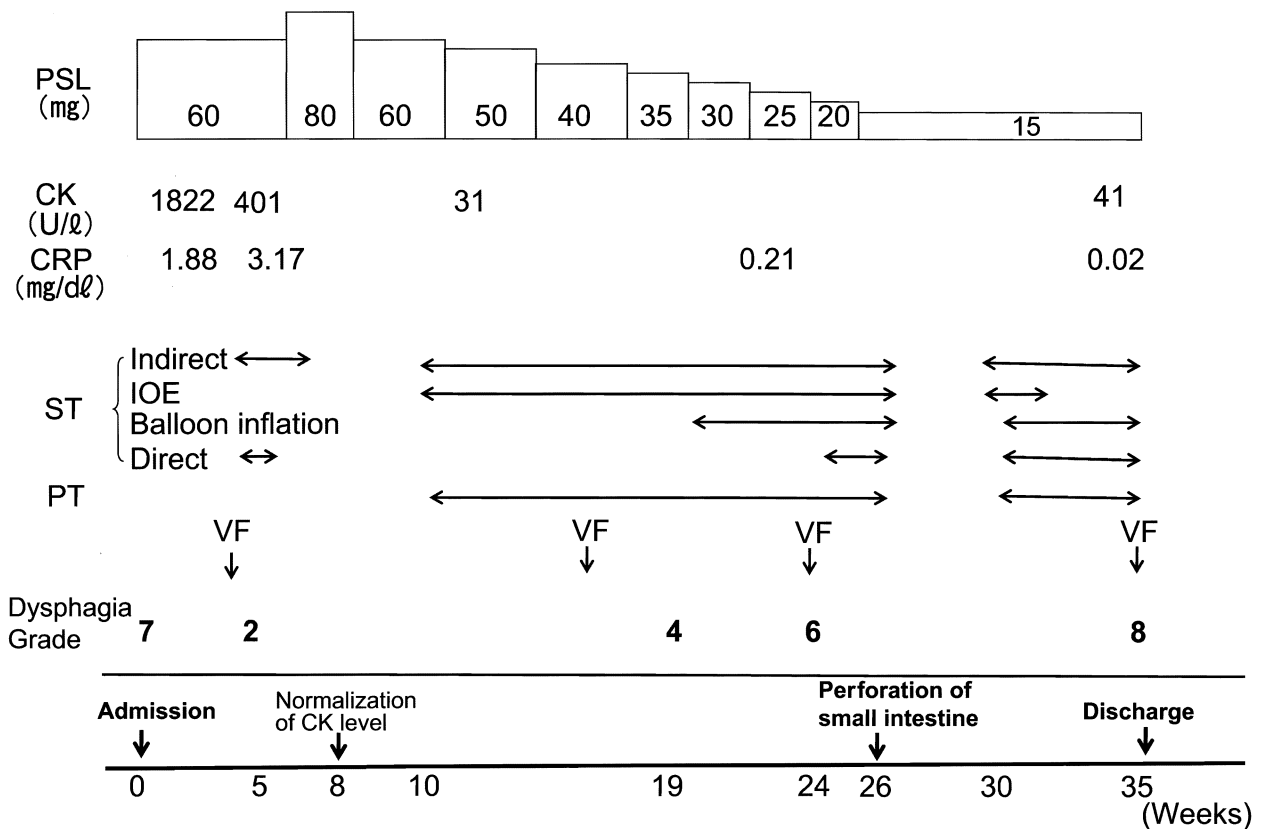


Fig. 1. Clinical Course  
 PSL: prednisolone, ST: speech-language-hearing therapy, PT: physical therapy,  
 VF: video fluorography, IOE: intermittent oro-esophagus catheterization,  
 CK: creatine kinase, CRP:c-reactive protein,  
 Dysphagia grade is expressed according to Fujishima's grading system

for 30 seconds) and modified water swallowing test (MWST) (5) were graded as profile 3a. These findings indicated the existence of a moderate grade of swallowing dysfunction. Videofluoroscopic examination of swallowing (VF) at 5 weeks after admission revealed decreased laryngeal elevation and epiglottis folding, reduced vocal cord adduction, a decline in pharyngeal contraction, delayed swallowing reflex, constricted space between the pharynx and upper esophagus, and retention of food in the vallecula. VF also showed disturbed relaxation of the upper esophageal sphincter and aspiration to the airway after swallowing. The cough reflex timing was delayed a few seconds after aspiration of food, although it was strong enough to remove the aspirated food out of the airway. Esophageal motor function was considered to be intact by VF assessment.

The nutrition status of this patient worsened after admission, and the serum levels of total protein and albumin at 10 weeks after admission were 5.4g/dl and 2.5 g/dl, respectively. Therefore, at 10 weeks after

admission, we introduced intermittent oro-esophageal tube feeding (IOE) for the intake of nutrients and swallowing training, since IOE can be easily performed without gag reflex induced by pharyngeal stimulation. IOE was performed using the PHYCON<sup>®</sup> feeding tube (Fuji Systems Corporation, Tokyo, Japan). In addition, injected nutrients through IOE were considered to easily reach to the patient's stomach, since his esophageal movement was not impaired. Balloon inflation therapy was performed using a 14 Fr urinary catheter. He could perform IOE by himself within a few days, and began both the balloon inflation therapy and synchronized pulling-out therapy (4) to enlarge the constricted space between the pharynx and the upper esophagus. The patient was continuously encouraged by the medical staff of our hospital to perform IOE, although the patient was annoyed by steroid therapy-induced, manic-depressive psychological status which hindered continuous swallowing rehabilitation. The patient's dysphagia gradually improved and VF at 13 weeks after the start of

IOE revealed the patient was able to swallow a small amount of jelly without aspiration. The patient could take rice gruel 3 times a day and although he was operated on for perforation of a steroid therapy-induced small intestine ulcer at 26 weeks after admission. IOE was discontinued at 30 weeks after admission because swallowing function and nutritional status of this patient became better, and the serum levels of total protein and albumin at that time were 6.1g/dl and 3.7g/dl, respectively. The patient was eventually discharged from our hospital at 35 weeks after admission.

## DISCUSSION

Swallowing disorder is a serious problem for patients, since it easily induces several life-threatening complications such as malnutrition and aspiration pneumonia. Swallowing abnormalities could be caused by numerous disease conditions, and swallowing rehabilitation should be programmed to fit the type and the individual patient's degree of swallowing dysfunction. This might require the involvement of several medical staff including speech-language-hearing therapists, physical therapists, occupational therapists, dietitians, and rehabilitation nurses. Dysphagia is a well-known symptom in patients with dermatomyositis, and this swallowing dysfunction was reportedly caused by decreased pharynx peristalsis, impaired upper esophagus relaxation and esophageal motility disorders (7-9). Research found esophageal motor dysfunction to be caused by a fibrosis in the cricopharyngeal muscle and tissue around the upper esophagus (10). However, standard protocol of swallowing rehabilitation for patients with dermatomyositis has not yet been determined.

We referred to the physical examination and VF findings to determine the methods of swallowing rehabilitation for our patient. Using VF assessment, we considered the swallowing dysfunction of this patient to be mainly caused by abnormalities of the pharyngeal stage in deglutition. We also found the esophageal stage in deglutition was not impaired. In addition, IOE technique was easily introduced for this patient, since pharyngeal sensation and gag reflex were absent at the start of IOE therapy. Nutrition therapy using IOE gradually improved the nutritional status of this

patient, and repeated IOE was considered to be effective to enhance the pharynx muscle function. The constricted space between pharynx and upper esophagus was also gradually enlarged by the balloon technique and pulling-out method synchronized with swallowing. The patient's swallowing dysfunction was successfully improved by this swallowing rehabilitation. The patient safely performed IOE, the balloon technique and pulling-out method by himself and these might have enhanced his motivation to continuously perform swallowing therapy. Therefore, IOE should be recognized as a useful rehabilitation therapy for the patients with swallowing dysfunction and malnutrition.

In conclusion, IOE is effective to improve nutrition status and swallowing function for patients with swallowing dysfunction caused by the abnormalities of pharyngeal stage in deglutition.

## REFERENCES

- 1) Hoshino I and Okamoto M (1997) Radiologic study of dysphagia in dermatomyositis and polymyositis. *The Oto-rhino-and laryngological clinic* 90: 1163-1167 (in Japanese).
- 2) Kisa T, Igo M, Inagawa T, Fukuda M, Saito J and Setoyama M (1997) Intermittent oral catheterization (IOC) for dysphagic stroke patients. *Jpn J Rehabil Med* 34: 113-120.
- 3) Fujishima I (1998) Rehabilitation for swallowing disorders associated with stroke, 2<sup>nd</sup> ed., pp85-86, Ishiyaku Publishers, Inc., Japan (in Japanese).
- 4) Oguchi K, Saitoh E, Baba M, Kusudo S, Tanaka T and Onogi K (2000) The repetitive saliva swallowing test (RSST) as a screening test of functional dysphagia (2) Validity of RSST. *Jpn J Rehabil Med* 37: 383-388.
- 5) Fujishima I (2003) Pocket Manual of Dysphagia, 2<sup>nd</sup> ed. (Dysphagia Team of Seirei Mikatahara General Hospital.,ed.) pp25-41, Ishiyaku Publishers, Inc., Japan (in Japanese).
- 6) Inagawa T and Yamada M (2005) Balloon catheter treatment methods. *J Clin Rehabil* 14: 443-448 (in Japanese).
- 7) St.Guily JL, Perie S, Willing TN, Chaussade S, Eymard B and Angelard B (1994) Swallowing disorders in muscular diseases: functional assessment

- and indication of cricopharyngeal myotomy. *Ear Nose Throat J* 73: 34-40.
- 8) De Merieux P, Verity MA, Clements PJ and Paulus HE (1983) Esophageal abnormalities and dysphagia in polymyositis and dermatomyositis. *Arthritis Rheum* 26: 961-968.
- 9) Horowitz M, McNeil JD, Maddern GJ, Collins PJ and Shearman DJ (1986) Abnormalities of gastric and esophageal emptying in polymyositis and dermatomyositis. *Gastroenterology* 90: 434-439.
- 10) Jacob H, Berkowitz D, McDonald E, Bernstein LH and Beneventano T (1983) The esophageal motility disorder of polymyositis. A prospective study. *Arch Intern Med* 143: 2262-2264.