

Helical CT With Oral Contrast Material for Imaging of Suspected Appendicitis and the Role of Mechanical Bowel Preparation for Appendectomy

Muneaki SHIBAKITA¹⁾, Yoshinari MAKINO²⁾ and Masaaki UCHIDA²⁾

¹⁾*Department of Surgery, Kawasaki Hospital, Kobe 652-0042, Japan*

²⁾*Department of Surgery, Matsue Seikyo Hospital, Matsue 690-0017, Japan*

(Received December 3, 2009; Accepted December 14, 2009)

We evaluated the accuracy and the efficiency of a focused computed tomography technique with contrast material administered by mouth for the diagnosis of appendicitis. Sixty three patients prospectively underwent appendiceal CT scans after meglumine diatrizoate solution as contrast material and polyethylene glycol as mechanical bowel preparation were administered by mouth for suspected appendicitis. This focused appendiceal CT technique proved to have a sensitivity of 92.9%, specificity of 100%, and accuracy of 98.1%, respectively.

The risk and difficulty of this method have been minimized, while diagnostic accuracy for appendicitis has been maintained. In addition, the advantage of this technique enables to perform the mechanical bowel preparation which reduce the infectious morbidity after appendectomy at the same time.

Key words: Appendicitis, Helical CT, Oral contrast material, Bowel preparation

INTRODUCTION

The diagnosis or exclusion of appendicitis is a common clinical problem. Reported rates of negative findings at diagnostic laparotomy in patients with diagnosed clinically range between 3% and 27% (1). Several diagnostic aids have been developed to improve diagnosis in suspected appendicitis including ultrasonography and computer tomography (CT). CT is 93 to 98% accurate in confirming or ruling out appendicitis (2-5). Recently, one pioneer studies by

Rao et al. have evaluated helical CT combined with contrast material administered through the colon and by mouth (6). In this study, CT had a sensitivity of 100%, a specificity of 95%, a positive predictive value of 97%, a negative predictive value of 100%, and an accuracy of 98%. Rao et al. further examined the accuracy of appendiceal CT combined with contrast material administered only through the colon, resulting in a sensitivity of 98%, a specificity of 98%, an accuracy of 98%, and a normal appendix identification of 94% (7). In his study, he argues that limitation of contrast material administered only by mouth include a relatively long delay before scanning and potential patient discomfort. However, reexamination of CT scanning performed with oral contrast material alone is required, since this method is very simple and non-invasive procedure compared with rectal contrast material administered into the colon through a rectal catheter.

Wound infection and intra-abdominal abscess remain significant cause of morbidity following appendectomy. A range of wound infection and intra-abdominal abscess rates after appendectomy has reported from 5.1 to 33.3% (8) and 1.4 to 2.2% (9, 10). Preoperative mechanical bowel preparation which was established as a standard for elective colorectal surgery was mainly introduced to diminish the infectious risks inherent to colorectal surgery and to improve operative handling of the bowel. The role of bowel preparation, however, has not been investigated in patients with appendicitis.

The first purpose of this study was to evaluate the accuracy and efficiency of CT combined with contrast material administered only by mouth. Second, we would like to examine the infectious risks after mechanical bowel preparation using polyethylene glycol solution given concomitantly with contrast material by mouth in patients with appendicitis.

Correspondence: Dr. Muneaki Shibakita, Department of Surgery, Kawasaki Hospital, Higashiyama-cho 3-3-1, Hyogo, Kobe 652-0042, Japan

Tel: +81-78-511-3131

Fax: +81-78-511-3138

E-mail: shibakita_muneaki@kawasaki-hospital-kobe.or.jp

MATERIALS AND METHODS

Sixty three patients with clinically suspected appendicitis prospectively underwent CT examination of the appendix at the Department of Surgery, Matsue Seikyo Hospital during the 4-years period from March 1999 to January 2003. There were 34 female (54.0%) and 29 male (46.0%) patients. There were 19 pediatric patients (ages 6-18 years) (30.2%) and 44 adult patients (69.8%) (mean age, 27.9 years; range 6-91 years). Each patient had several typical clinical signs and symptoms associated with appendicitis (Table 1). Patients with abdominal pain that was considered to be due to obstruction and pregnant women were excluded.

The patient preparation involved oral administration of a solution made up of 68g of polyethylene glycol (Niflec, Ajinomoto Pharma, Ltd., Tokyo, Japan) and 50ml of 76% meglumine diatrizoate solution (Gastrografin, Schering, Germany) mixed in 1000ml of water. Once a patient had a bowel movement, helical CT scanning of lower part of abdomen was performed with 5-mm collimation, whether the patient received all of oral medium or not. The total amount of oral intake and bowel preparation time were recorded. No patient initially received contrast material administered intravenously or through the colon. Written Informed consent was obtained from all the patients.

A radiologist, with no previous knowledge of the clinical symptoms, interpreted CT study in all patients. The CT diagnosis of appendicitis was based on the visualization of an enlarged appendix that filled with neither air nor contrast material (Fig. 1). Appendiceal CT scans were interpreted as negative for appendicitis if the appendiceal lumen filled completely with contrast material, air, or both without appendiceal wall thickness (Fig. 2). The radiology reports and the medical records of all sixty three patients were reviewed. The surgeon's decisions to perform surgery were

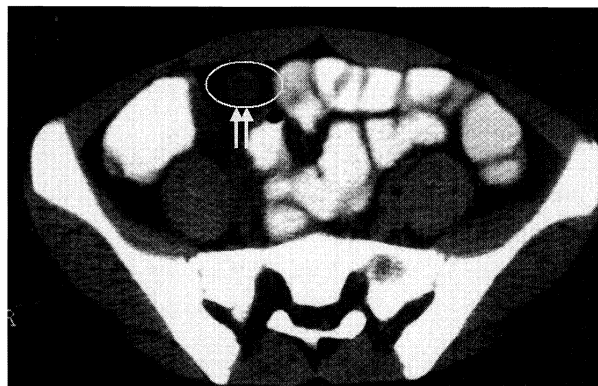


Fig. 1. CT scan in patient (36years old, male, WBC: 12500, CRP:4.7) with acute appendicitis. CT scan at the cecal level shows an enlarged appendix that filled with neither air nor contrast material.

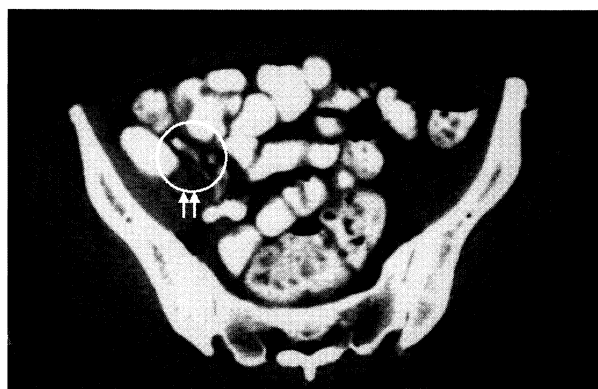


Fig. 2. CT scan in patient (42years old, female, WBC: 11100, CRP:2.2) with normal appendix. CT scan at the cecal level displays a contrast material-filled normal appendix without appendiceal wall thickness.

based on a combination of their clinical assessment of the patient's condition and CT examination results. The final diagnosis of appendicitis was confirmed histologically in resected specimens. The CT findings were compared with the pathologic findings. Postoperative complication including wound infection and intra-abdominal abscess were recorded. If surgery was not performed, clinical follow-up was obtained. To our knowledge, appendectomy was not performed on any of the patients with a negative CT scan.

RESULTS

Of the 63 patients, the oral contrast material reached the terminal ileum and cecum in fifty nine patients (93.7%) (adult patients ; 97.7%, 43cases, pediatric patient ; 84.2%, 16cases). Cecal opacification was not present in four patients. Three of them were

Table 1. Clinical signs and symptoms in 63 patients with suspected appendicitis

Signs and symptoms	No.	Occurrence (%)
Right lower quadrant pain	54	85.7
WBC > 10000/mm ³	33	52.4
CRP > 1.0mg/dl	35	55.6
Fever >37.0°C	36	57.1

pediatric patients. The median volume of received oral contrast material was 500ml. (adult patients ; 650ml, pediatric patients ; 350 ml). The median time of bowel preparation including the time required to administer contrast material by mouth and scan the patient was 86 minutes (adult patients ; 77 minutes, pediatric patients ; 134.5 minutes) (Table 2). The symptoms including abdominal pain, nausea, and vomiting were not occurred in all patients during this procedure. Needless to say, no patients had aspiration of the contrast medium or gastric contents attributable to performance of the CT scan.

Nineteen patients had CT scans that were prospectively interpreted as positive for appendicitis (32.2%). Thirteen of these patients underwent surgery, and phlegmonous or gangrenous appendicitis were confirmed pathologically in all patients with 1 (7.7%) having a ruptured appendix. Forty patients had CT scans that were prospectively interpreted as negative for appendicitis. These 40 cases can be divided into those in which the appendiceal lumen filled with contrast media only in 31 cases (77.5%), with air only in 2 cases (5.0%), or collapsed in 7 cases (17.5%). Two patients whose CT scans were reported as normal went to surgery on clinical suspicion. One had a pathologically catarrhal appendix and the other who was taken to the operation room by a gynecologist with the presumptive diagnosis of a right ovarian cyst had a pathologically normal appendix. Summary of operation cases in patients with appendicitis is shown in Table 3.

Alternative diagnosis were identified on CT scans in 19 (47.5%) of 40 patients who did not have appendicitis, including mesenteric adenitis (9 patients), diverticulitis (six patients), ovarian cystic disease (two patients), right-sided colitis (two patients)

Table 2. The median time of bowel preparation including the time required to administer contrast material by mouth and CT scan and the median volume of received oral medium

Bowel preparation time	
all patients	85 min. (111.9 + 80.2 min.)*
Adult patients	77 min. (99.7 + 64.6 min.)
pediatric patients	134.5 min. (159.0 + 117.2 min.)
Total volume of received oral medium	
All patients	500 ml (594.1 + 339.1 ml)
Adult patients	650 ml (642.6 + 341.4 ml)
pediatric patients	350 ml (392.9 + 290.7 ml)

*(mean + SD)

(Table 4). Complications such as sepsis, intra-abdominal abscess, fistula, and reoperation occurred in no patients. However, wound infection was occurred only in one diabetic patient (6.7%) who had a pathologically gangrenous appendicitis This focused appendix CT technique proved to have a sensitivity of 92.9%, specificity of 100%, and accuracy of 98.1%, respectively.

Table 3. Summary of operation cases in patients with appendicitis

Pt.	age	sex	CT finding	pathology	complication
1,	27	M	appendicitis	phlegmonous	none
2,	17	F	appendicitis	phlegmonous	none
3,	36	M	appendicitis	phlegmonous	none
4,	59	M	appendicitis	gangrenous	yes*
5,	25	M	appendicitis	phlegmonous	none
6,	91	F	appendicitis	phlegmonous	none
7,	20	F	appendicitis	phlegmonous	none
8,	19	F	appendicitis	phlegmonous	none
9,	13	F	appendicitis	gangrenous	none
10,	70	M	appendicitis	phlegmonous	none
11,	13	F	appendicitis	phlegmonous	none
12,	28	M	appendicitis	phlegmonous	none
13,	17	M	appendicitis	phlegmonous	none
14,	35	F	ovarian cyst	normalis	none
15,	40	F	adenitis	catarrhalis	none

*wound infection

Table 4. CT diagnosis in 59 patients with suspected appendicitis

CT diagnosis	Number
Appendicitis	19 (32.2%)
Normal appendix	40 (67.8%)
mesenteric adenitis	9
diverticulitis	6
ovarian cystic disease	2
right-sided colitis	2

DISCUSSION

The study demonstrates that abdominal CT can be used to increase diagnostic accuracy in patients with suspected appendicitis in whom the diagnosis could not be ruled out based on history, physical examination, and laboratory data. Malone et al in 1993 used an unenhanced CT technique limited to the right lower quadrant region; they reported a sensitivity of 87%, a specificity of 97%, a positive predictive value of 94%, a negative predictive value of 93%, and an accuracy of 93% for the diagnosis of appendicitis (3). Routine appendiceal CT performed in patients who presented with suspected appendicitis improved patient care and reduced the use of hospital resources, because the savings achieve by eliminating

unnecessary operations and hospitalization for observation outweighs the cost of routine appendiceal CT (11).

It has been demonstrated in several studies that the technique of helical CT combined with contrast material administered through the colon and by mouth was evaluated and proved to be more accurate than the technique of helical CT without any contrast material (16,12). In this study, CT combined with contrast material had a sensitivity of 100%, a specificity of 95%, and an accuracy of 98% (6). The advantage of this method is visualization of the normal appendix filled with contrast material. Rao *et al.* argues that advantages of not administering contrast material by mouth include immediate patient scanning and eliminating any potential patient discomfort (nausea and vomiting) that can be associated with full-dose contrast material administered by mouth (7). In addition, other study shows that the normal appendix is more likely to fill when colon contrast medium is administered, as opposed to administration of oral contrast medium alone (13). However, reexamination of CT scanning performed with oral contrast material alone is required, since this method is very simple and non-invasive compared with rectal contrast material administered into the colon through a rectal catheter.

In our study, 63 patients with clinically suspected appendicitis underwent focused appendiceal CT after receiving oral contrast material alone. During this procedure, the symptoms including abdominal pain, nausea, and vomiting did not occur in all patients. The safety of oral contrast media in patients who may need emergency surgery is also well documented (14). In our study, oral administration of 500ml of contrast material before CT scanning enables opacification of cecum (adult patients ; 650ml, pediatric patients ; 350 ml). This figure is low compared with rectal administration of up to 900ml (7). The median time of bowel preparation including the time required to administer contrast material by mouth and scan the patient was 86 minutes. A minor disadvantage of our technique is that patients wait over one hour before CT scanning. Rao *et al.* reported that the CT examinations with rectal contrast material were completed in less than 15 minutes (7). If an immediate study was required, only rectal contrast material seems to be effective. However, a range of appendiceal

perforation rates has reported from 10% to 34% (15-17). The perforation rate of 7.7% in our series does not support the hypothesis that preoperative oral intake of contrast material and relatively delay before scanning might contribute to an increase in perforation rate.

The oral contrast material reached the terminal ileum and cecum in fifty nine patients (93.7%) and the rate of appendiceal lumen filled with contrast media or air is 77.5% in the normal appendix in our study. These data are similar or high compared with the data after receiving contrast material through the colon in previous studies (cecal opacification ; 93.0%, appendiceal lumen patency ; 73%) (7). This focused appendix CT technique in our study proved to have a sensitivity of 92.9%, specificity of 100%, and accuracy of 98.1%, respectively. Despite improved simple and non-invasive technique, diagnostic accuracy was maintained.

The main infectious complications encountered after appendectomy include wound infection and intra-abdominal abscess. A range of wound infection and intra-abdominal abscess rates after appendectomy has reported from 5.1 to 33.3% (8) and 1.4 to 2.2% (9,10). In our present study, all patients received a mechanical bowel preparation using polyethylene glycol solution with oral contrast material before appendectomy. Preoperative mechanical bowel preparation for colorectal surgery is commonly practiced by most surgeons. With the current common practice, the rate of infectious complication such as wound infection and intra-abdominal abscess after colorectal surgery has been reduced to 6 to 25 percent with mechanical bowel preparation (18-20). However, to our knowledge there have been no reports published to date regarding the effect of bowel preparation in appendiceal patients. In our study, intra-abdominal abscess occurred in no patients and wound infection occurred only in one diabetic patient (6.7%) who had a pathologically gangrenous appendicitis. This data shows that preoperative bowel preparation reduced infectious morbidity after appendectomy. In addition, the other role of bowel preparation for colorectal surgery are to prevent mechanical disruption of the anastomosis by the passage of hard feces and to improve handling of the bowel during the procedure by removing the bulky intraluminal contents. If the appendiceal or cecal

carcinoma is seen through to have acute appendicitis intraoperatively, it seems to be safe to perform the resection of colon after mechanical bowel cleansing.

In conclusion, we have found that helical CT with oral contrast material has high sensitivity and specificity for the examination of patients with suspected appendicitis. The risk and difficulty of this method have been minimized, while diagnostic accuracy for appendicitis has been maintained. In addition, the advantage of this technique enables to perform the colon preparation which reduces the infectious morbidity after appendectomy at the same time.

REFERENCES

- 1) Jones PF (2001) Suspected acute appendicitis: trends in management over 30 years. *Br J Surg* 88: 1570-1577.
- 2) Balthazar EJ, Megibow AJ, Siegel SE and Birnbaum BA (1991) Appendicitis: prospective evaluation with high-resolution CT. *Radiology* 180: 21-24.
- 3) Malone AJ, Wolf CR, Malmed AS and Melliore BF (1993) Diagnosis of acute appendicitis: value of unenhanced. *AJR* 160: 763- 766.
- 4) Balthazar EJ, Birnbaum BA, Yee J, Megibow AJ, Roshkow J and Gray C (1994) Acute appendicitis: CT and US correlation in 100 patients. *Radiology* 190: 31-35.
- 5) Lane MJ, Katz DS, Ross BA, Clautice-Engle TL, Mindelzun RE and Jeffrey RB (1997) Unenhanced helical CT for suspected acute appendicitis. *AJR* 168: 405-409.
- 6) Rao PM, Rhea JT, Novelline RA, McCabe CJ, Lawrason JN, Berger DL and Sacknoff R (1997) Helical CT technique for the diagnosis of appendicitis: Prospective evaluation of a focused appendix CT examination. *Radiology* 202: 139-144.
- 7) Rao PM, Rhea JT, Novelline RA, Mostafavi AA, Lawrason JN and McCabe CJ (1997) Helical CT combined with contrast material administered only through the colon for imaging of suspected appendicitis. *AJR* 169: 1275-1280.
- 8) Krukowski ZH, Irwin ST, Denholm S and Matheson NA (1988) Preventing wound infection after appendectomy: a review. *Br J Surg* 75: 1023-1033.
- 9) Wullstein C, Barkhausen S and Gross E (2001) Results of laparoscopic vs. conventional appendectomy in complicated appendicitis. *Dis Colon Rectum* 44: 1700-1705.
- 10) Okoye BO (1998) Rampersad B, Marantos A, Abernethy LJ, Losty PD, Lloyd DA. Abscess after appendectomy in children: the role of conservative management. *Br J Surg* 85: 1111-1113.
- 11) Rao PM, Rhea JT, Novelline RA, Mostafavi AA and McCabe CJ (1998) Effect of computed tomography of the appendix on treatment of patients and use of hospital resources. *N Engl J Med* 338: 141-146.
- 12) Rao PM, Wittenberg J, McDowell RK and Rhea JT (1997) Appendicitis: Use of arrowed sign for diagnosis at CT. *Radiology* 202: 363-366.
- 13) Curtin KR, Fitzgerald SW, Nemcek AA, Hoff FL and Vogelzang RL (1995) CT diagnosis of acute appendicitis: imaging findings. *AJR* 164: 905-909.
- 14) Federle MP, Peizman A and KrughJ (1995) Use of oral contrast material in abdominal trauma CT scans: is it dangerous? *J Trauma* 38: 51-53.
- 15) Temple CL, Huchcroft SA and Temple WJ (1995) The natural history of appendicitis in adults: a prospective study. *Ann Surg* 221: 278-281.
- 16) Luckmann R (1989) Incidence and case fatality rates for acute appendicitis in California: a population-based study of the effects of age. *Am J Epidemiol* 129: 905-918.
- 17) Braveman P, Schaaf M, Egerter S, Bennett T and Schecter W (1994) Insurance-related differences in the risk of ruptured appendix. *N Engl J Med* 331: 444-449.
- 18) Longo WE, Virgo KS, Johnson FE, Oprian CA, Vernava AM and Wada TP (2000) Risk factors for morbidity and mortality after colectomy for colon cancer. *Dis Colon Rectum* 43: 83-91.
- 19) Coppa GF and Eng K (1988) Factors involved in antibiotic selection in elective colon and rectal surgery. *Surgery* 104: 853-858.
- 20) Dawes LG, Aprahamian C, Condon RE and Malangoni MA (1986) The risk of infection after colon injury. *Surgery* 100: 796-803.