

LIVER ABSCESS FOLLOWING ABLATION THERAPIES FOR METASTATIC LIVER TUMOR AFTER BILIARY RECONSTRUCTION: REPORT OF TWO CASES

Seiji YANO, Yoshinori NIO, Masayuki ITAKURA, Tomoko ITAGAKI, Takeshi NISHI, Yoshiki KATAOKA, Shinichiro ENDO, Makoto KOIKE, Koji HASHIMOTO and Tetsuya HIGAMI

Department of Cardiovascular and Digestive Surgery, Shimane University Faculty of Medicine, Enyacho 89-1, Izumo 693-8501 Japan

(Accepted March 15, 2005)

Two cases of liver abscess following ablation therapies for metastatic liver tumor after biliary reconstruction are reported. Case 1; A 58-year-old man underwent pylorus preserving pancreatoduodenectomy for cholangiocarcinoma. Microwave coagulation therapy was performed for metastatic liver tumor; however, liver abscess developed after one month and became recurrent. Case 2; A 67-year-old woman underwent pylorus preserving pancreatoduodenectomy for periampullary cancer. Radio frequency ablation was performed for metastatic liver tumor; however, liver abscess developed after one week. In Case 1, we believe that cholangitis at the peripheral level of the intrahepatic biliary tree spread to the treated area and altered blood flow caused recurrence of liver abscess. In Case 2, cholangitis could have been directly transferred to the ablated area through between the abscess and intrahepatic bile duct.

In conclusion, ablation therapies could promote the development of liver abscess in patients who have undergone biliary tract reconstruction after tumor resection and might be contraindicated in such patients.

Key words: liver, abscess, ablation

INTRODUCTION

Recently, ablation therapies (ATs) in the form of microwave coagulation therapy (MCT), radio frequency ablation (RFA) and cryosurgical ablation

(CSA) have come into wide use for liver carcinoma. Although liver abscess (LA) has been reported as one of the complications of ATs (1-4), these procedures are regarded as safe and minimally invasive compared with surgical treatment (1-4). On the other hand, patients undergoing biliary reconstruction accompanied by pylorus preserving pancreatoduodenectomy (PpPD) are always exposed to the risk of cholangitis (5-8). In this condition, LA can readily occur after ATs.

The authors herein report two cases of LA after ATs for metastatic liver tumors treated by PpPD with biliary reconstruction.

Case 1: A 58-year-old man underwent PpPD for bile duct cancer in July, 2000. Biliary reconstruction was performed by hepaticojejunostomy. Four months after surgery, computed tomography (CT) revealed multiple low-density areas (LDA) in both lobes of the liver (1~3cm in diameter) (Fig. 1a). The serum tumor marker carbohydrate antigen (CA) 19-9, was elevated at 4590 U/ml (upper limit of normal, 37 U/ml). The patient was hospitalized in December 2000. At laparotomy, MCT was performed (60~80 W, 60 sec, about 80 times). A catheter was also placed in the proper hepatic artery and a reservoir was implanted in the right subcutaneous inguinal region in order to deliver a chemotherapy infusion to the liver metastases. However, a fever developed a month after MCT, and despite several days' treatment with antibiotics, the patient's condition gradually deteriorated. Laboratory data showed leukocytosis (12 000 / μ l) and elevated C-reactive protein (CRP) (14.0 mg/dl, normal < 0.2 mg/dl) (Fig. 2). CT demonstrated abscess formation at the MCT locus and percutaneous transhepatic abscess drainage

Correspondence: Seiji Yano, MD, Department of Cardiovascular and Digestive Surgery, Shimane University Faculty of Medicine, Enya-cho 89-1, Izumo 693-8501 Japan

Tel: +81-853-20-2225

Fax: +81-853-20-2222

E-mail: yano@med.shimane-u.ac.jp

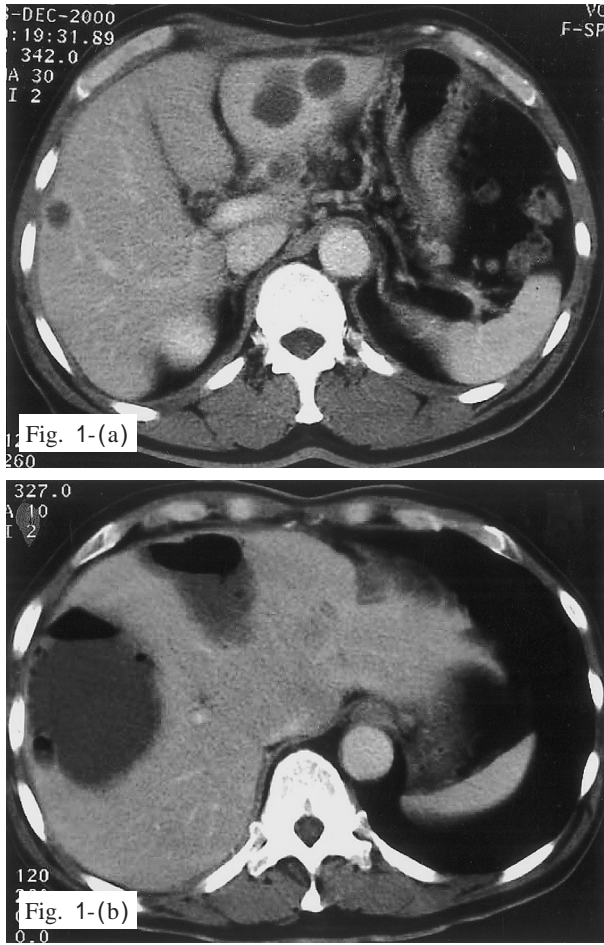


Fig. 1. (a) Computed tomography shows multiple low-density areas (1~3 cm diameter in the both lobes of the liver. (b) Computed tomography shows abscess formation in the liver (a month after MCT).

(PTAD) was consequently performed 5 weeks after MCT (Fig. 1b). Bacteriological examination of pus drained from the LA revealed alpha-Streptococcus and Pseudomonas aeruginosa. In addition to drainage, antibiotic agents were also infused to the liver from the reservoir. Nevertheless, despite this intensive treatment, 3 months after MCT, CT revealed abscess formation at different sites. PTAD was repeated and drainage tube imaging showed pooling of contrast medium in the LA and no flow through the intrahepatic bile duct (Fig. 5a). Angiography demonstrated encasement of the proper hepatic artery due to invasion of the tumor. The patient finally developed hepatic failure and died 8 months after MCT.

Case 2: A 67-year-old woman underwent PpPD for periampullary cancer in August 2001. Biliary reconstruction was performed using choledochojejunostomy. A year after surgery, CT revealed a solitary LDA in hepatic segment V (Couinaud's S5, 2.0 cm in diameter) (Fig. 3a) and CA 19-9 was measured at 180 U/ml. The patient was hospitalized in October 2001. Needle biopsy under the ultrasound guidance was performed and histological examination showed adenocarcinoma. Percutaneous RFA was immediately performed using ultrasonography (total duration 32 min). A fever developed the day after the procedure,

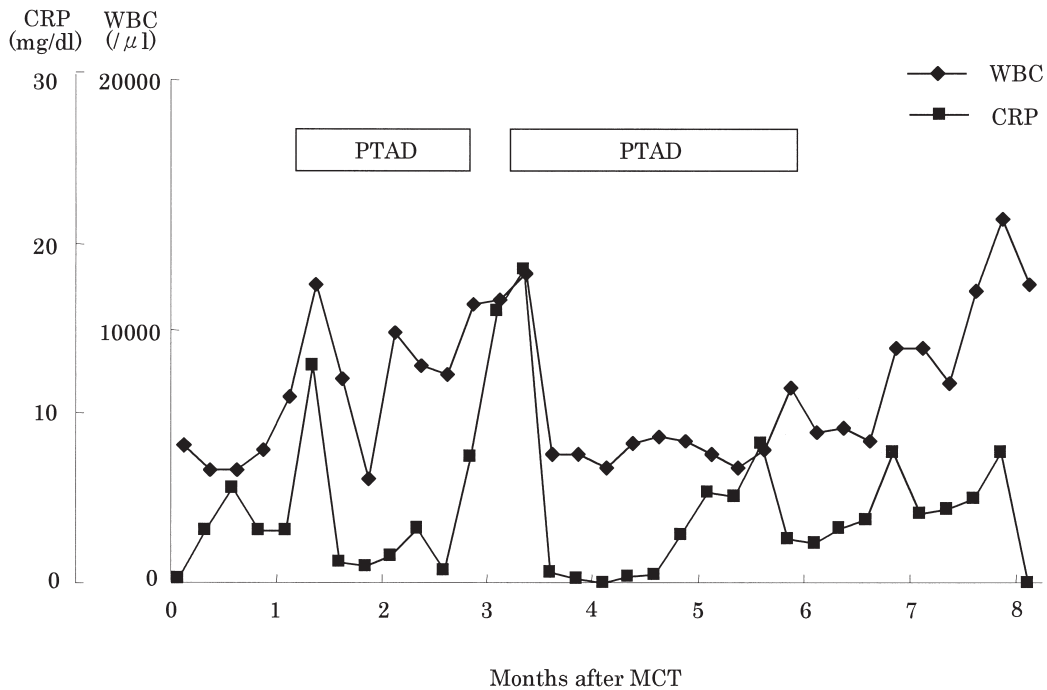


Fig. 2. Clinical course: case 1

PTAD; percutaneous transhepatic abscess drainage CHDF; continuous hemodialysis filtration

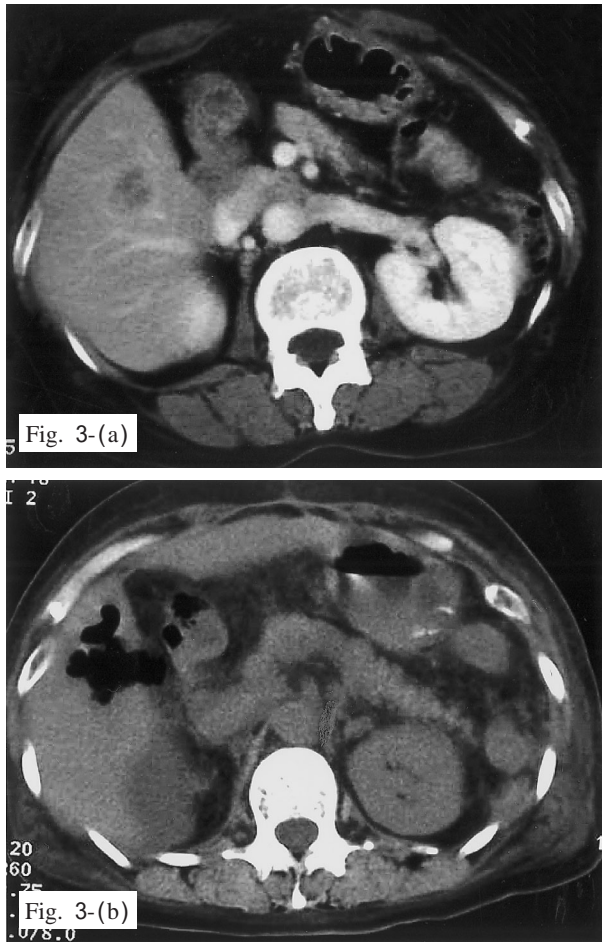


Fig. 3. (a) Computed tomography shows a solitary 2.0 cm diameter low-density area in S5 of the liver, (b) Computed tomography shows an abscess formation with gas in S5 of the liver (a week after RFA).

and despite the administration of antibiotics, the patient gradually developed disseminated intravenous coagulation syndrome. Laboratory data revealed leukocytosis (51,600/ μ l) and elevated levels of CRP (10.6 mg/dl) and endotoxin (7.1 pg/ml, normal <5.0 pg/ml). Marked thrombocytopenia (5000/ μ l) was also evident, with low fibrinogen (234 mg/dl) and raised FDP (37.2 μ g/ml)(Fig. 4). As CT revealed abscess formation with gas at the RFA locus (Fig. 3b), PTAD was performed under ultrasonography on the 7th day post-RFA. Bacteriological examination of pus demonstrated *Enterobacter aerogenes*. In addition to drainage, continuous hemodialysis filtration was performed for 6 days and endotoxin absorption therapy was carried out twice. After 10 days of intensive care, the patient's condition improved and drainage tube imaging showed flow between the abscess and intrahepatic bile duct (Fig. 5b).

DISCUSSION

Ablation therapies (ATs) have been indicated for metastatic liver carcinoma and hepatocellular carcinoma in place of hepatic surgery. However, complications of ATs have been reported to include liver abscess (LA), biliary fistula, skin burn, hemorrhage, and liver failure (1-4). Among these, liver abscess

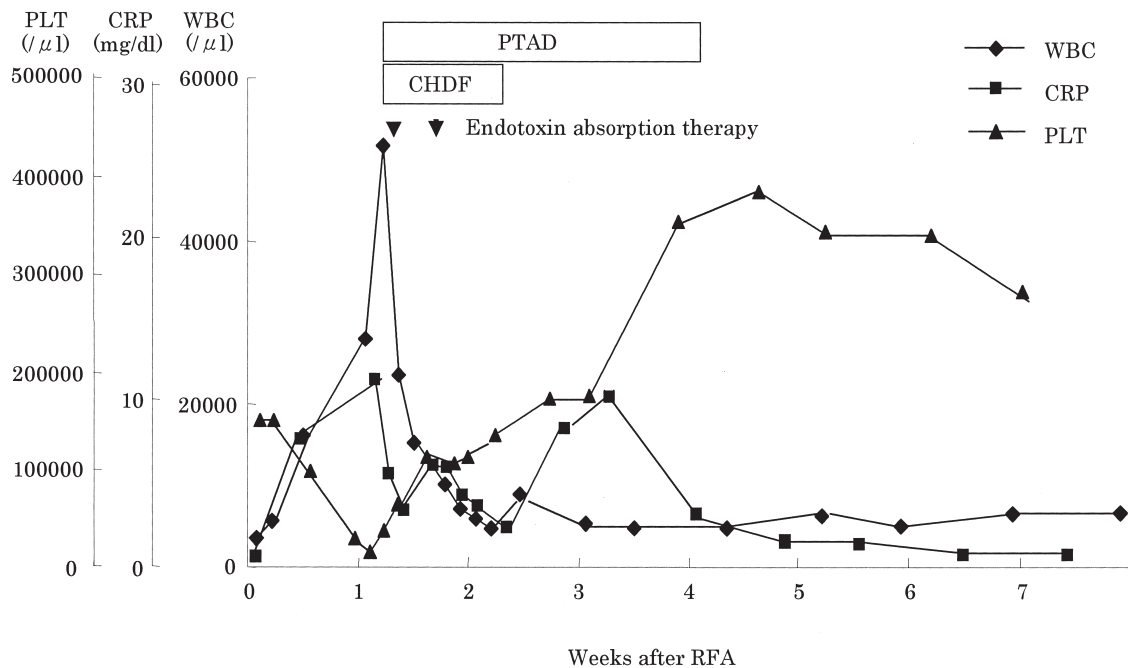


Fig. 4. Clinical course: case 2. PTAD; percutaneous transhepatic abscess drainage.

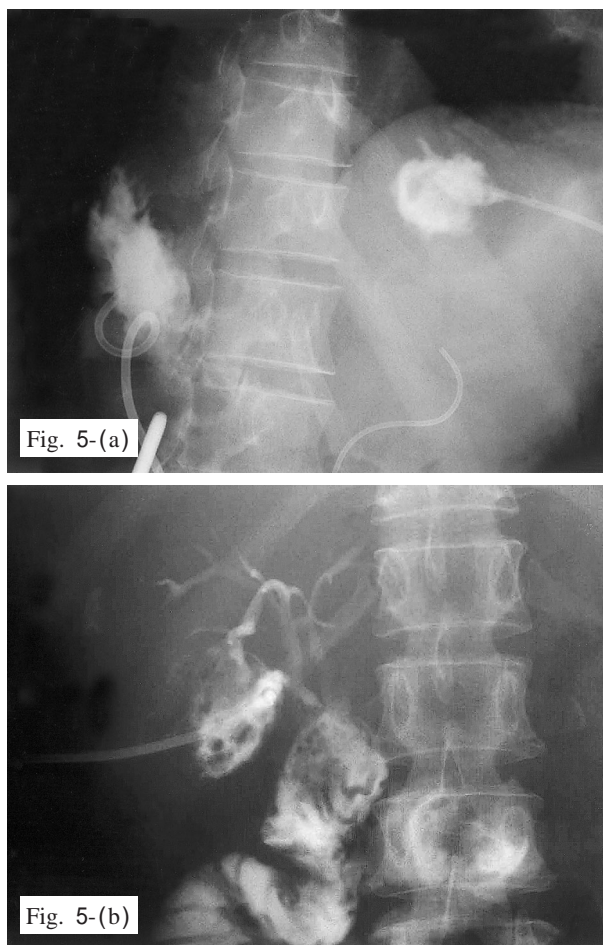


Fig. 5. (a) case 1: Drainage tube imaging shows pooling of contrast medium in the liver abscess and no flow through the intrahepatic bile duct (3 months after MCT). (b) case 2: Drainage tube imaging shows communication between the abscess and intrahepatic bile duct (4 weeks after RFA).

was the one of the main complications with an incidence reported by Shibata *et al.* (1) of 10% in MCT, and by McKinnon *et al.* (2) of 10% in cryosurgery. However, in series reported by Wood *et al.* (3) and Chan *et al.* (4), liver abscess occurred less frequently in RFA; in 2% and 1% of cases, respectively. In the cases presented in the current report, the most important problem was severe and recurrent LA.

PD and PpPD are often indicated as surgical approaches to biliary carcinoma and these operative procedures are accompanied by biliary reconstruction. Yamaguchi *et al.* (5) reported cholangitis (6.7%), and LA (1.2%) as late (more than 1 month after surgery) complications after PpPD. Furugaki (6) reported the incidence of LA after hepatobiliary and pancreatic surgery to be 0.6%. In addition, Ammori

et al. (7) recognized that the main cause of LA occurring after biliary tract reconstruction was biliary-enteric anastomotic strictures following PD. Furugaki *et al.* (6) also reported that anastomotic stricture developed in 5 patients, and that portal vein and hepatic artery obstruction due to intraoperative radiation occurred in 1 of 12 cases of LA after hepatobiliary and pancreatic surgery. Moreover, Kubo *et al.* (8) reported anastomosis with subsegmental bile ducts, and vascular reconstruction to represent risk factors for refractory LA occurring after PD or liver resection with biliary-intestinal anastomosis. Therefore, cholangitis after biliary reconstruction may be a very important cause of LA. Furthermore, bile stasis due to biliary-enteric anastomotic strictures and liver ischemia from hepatic vascular damage will accelerate the development of LA. In cases such as the two presented here, cholangitis due to biliary reconstruction performed by hepaticojejunostomy and choledochojejunostomy with PpPD often develops although biliary-enteric anastomotic strictures were not demonstrated.

Chen *et al.* (9) reported the incidence of LA after transarterial embolization for hepatocellular carcinoma to be 1.1%. Moreover, Kim *et al.* (10) reported that LA after hepatic chemoembolization occurred in 4.5% patients and that 6 of the 7 patients with abscesses had undergone Whipple procedure prior to chemoembolization. They suggested bilioenteric anastomosis to be the major determinant of LA formation after hepatic chemoembolization. In addition, Song *et al.* (11) reported that biliary abnormality leading to a susceptibility to ascending biliary infection was the most important predisposing factor to the development of LA after transcatheter oily chemoembolization and that risk factors. In the two cases described here, Case 1 may have developed liver ischemia due to tumor invasion causing stenosis of the proper hepatic artery, which lead to recurrence of LA.

LA following ATs for metastatic liver tumor after biliary reconstruction have only been reported by Yamamoto *et al.* (12) and Morimoto *et al.* (13). Yamamoto *et al.* (12) reported an autopsy case of sepsis following RFA for metastatic liver carcinoma after bile duct reconstruction. This case revealed necrotic liver abscess at the RFA locus and multiple

microabscesses of the liver, heart, and kidney; the mechanism of LA formation was thus shown to be retrograde cholangitis. Morimoto *et al.* (13) reported LA formation after MCT undertaken for hepatic metastases from surgically excised bile duct cancer. They concluded that causes of LA formation could include the following: the formation of necrotic materials in the liver due to MCT, flow through the intrahepatic bile duct, a retrograde infection from the hepatocholangiojejunostomy division, and bile duct stenosis or necrosis due to lymphadenectomy of the hepatoduodenal ligament or occlusion of the hepatic artery.

Although LA appears to have various causes, biliary reconstruction is often associated with chronic infection, and as destruction of intrahepatic bile duct occurs in ATs, bacteria from areas affected by cholangitis can easily transfer to damaged areas of the liver. In Case 1, no flow was demonstrated through the intrahepatic bile duct and stenosis of proper hepatic artery was seen after MCT. Therefore, the authors believe that cholangitis at the peripheral level of the intrahepatic bile duct transferred to the MCT area and that the altered blood flow lead to recurrence of LA. In Case 2, cholangitis may have been directly transferred to the area treated by RFA through the communication between the LA and intrahepatic bile duct (as in this case communication between the LA and intrahepatic bile duct was demonstrated)

In conclusion, the authors believe that severe LA occurs readily after ATs in patients who have undergone biliary tract reconstruction such as PpPD and that ATs may be contraindicated in patients with liver tumor after biliary tract reconstruction.

REFERENCES

- 1) Shibata T, Takami M, Fujimoto T, Takada T, Kitada M, Tsukahara Y, Okumura Y, Saito M, Murotani M, Sugimoto K (1992) An attempt at intraoperative, ultrasound-guided microwave tissue coagulation for metastatic liver tumors (in Japanese with English abstract). *Gan To Kagaku Ryoho (Jpn J Cancer Chemother)* 19: 1605-8.
- 2) McKinnon JG, Temple WJ, Wiseman DA, Saliken JC (1996) Cryosurgery for malignant tumours of the liver. *Can J Surg* 39: 401-6.
- 3) Wood TF, Rose DM, Chung M, Allegra DP, Foshag LJ, Bilchik AJ (2000) Radiofrequency ablation of 231 unresectable hepatic tumors: indications, limitations, and complications. *Ann Surg Oncol* 7: 593-600.
- 4) Chan RP, Asch M, Kachura J, Ho CS, Greig P, Langer B, Sherman M, Wong F, Feld R, Gallinger S (2002) Radiofrequency ablation of malignant hepatic neoplasms. *Can Assoc Radiol J* 53: 272-8.
- 5) Yamaguchi K, Tanaka M, Chijiwa K, Nagakawa T, Imamura M, Takada T (1999) Early and late complications of pylorus-preserving pancreatoduodenectomy in Japan 1998. *J Hepatobiliary Pancreat Surg* 6: 303-11.
- 6) Furugaki K, Chijiwa K, Ogawa T, Ogawa Y, Tanaka M (2001) Pyogenic liver abscess after hepatobiliary and pancreatic surgery. *Int Surg* 86: 67-71.
- 7) Ammori BJ, Joseph S, Attia M, Lodge JP (2000) Biliary strictures complicating pancreaticoduodenectomy. *Int J Pancreatol* 28: 15-22.
- 8) Kubo S, Kinoshita H, Hirohashi K, Tanaka H, Tsukamoto T, Kanazawa A (1999) Risk factors for and clinical findings of liver abscess after biliary-intestinal anastomosis. *Hepato-gastroenterology* 46: 116-20.
- 9) Chen C, Chen PJ, Yang PM, Huang GT, Lai MY, Tsang YM, Chen DS (1997) Clinical and microbiological features of liver abscess after transarterial embolization for hepatocellular carcinoma. *Am J Gastroenterol* 92: 2257-9.
- 10) Kim W, Clark TW, Baum RA, Soulen MC (2001) Risk factors for liver abscess formation after hepatic chemoembolization. *J Vasc Interv Radiol* 12: 965-8.
- 11) Song SY, Chung JW, Han JK, Lim HG, Koh YH, Park JH, Lee HS, Kim CY (2001) Liver abscess after transcatheter oily chemoembolization for hepatic tumors: incidence, predisposing factors, and clinical outcome. *J Vasc Interv Radiol* 12: 313-20.
- 12) Yamamoto K, Yahara N, Kawaoka T, Hayashi H, Hazama S, Tangoku A, Oka M (2002) An autopsy case of sepsis following radiofrequency ablation (RFA) for metastatic liver carcinoma after bile duct reconstruction (in Japanese with English abstract). *Gan To Kagaku Ryoho (Jpn J*

- Cancer Chemother) 29: 2238-41.
- 13) Morimoto O, Nagano H, Sakon M, Eguchi H, Miyamoto A, Kondo M, Arai I, Yamamoto T, Dono K, Umeshita K, Takamura M, Murakami T, Nakamori S, Nakamura H, Monden M (2002) Liver abscess formation after microwave coagulation therapy applied for hepatic metastases from surgically excised bile duct cancer: report of a case. *Surg Today* 32: 454-7.