



Review

Strategies to prevent hypertrophic scar formation: a review of therapeutic interventions based on molecular evidence

Eri Shirakami, Sho Yamakawa and Kenji Hayashida*

Division of Plastic and Reconstructive Surgery, Shimane University Faculty of Medicine, 89-1 Enya-cho, Izumo, Shimane 693-8501, Japan

*Correspondence. Email: tokimayu122710130311@gmail.com

Received 8 August 2019; Revised 28 August 2019; Editorial decision 15 September 2019

Abstract

Once scar tissues mature, it is impossible for the surrounding tissue to regenerate normal dermal tissue. Therefore, it is essential to understand the fundamental mechanisms and establish effective strategies to inhibit aberrant scar formation. Hypertrophic scar formation is considered a result of the imbalance between extracellular matrix synthesis and degradation during wound healing. However, the underlying mechanisms of hypertrophic scar development are poorly understood. The purpose of this review was to outline the management in the early stage after wound healing to prevent hypertrophic scar formation, focusing on strategies excluding therapeutic agents of internal use. Treatment aimed at molecular targets, including cytokines, will be future options to prevent and treat hypertrophic scars. More basic studies and clinical trials, including combination therapy, are required to investigate the mechanisms and prevent hypertrophic scar formation.

Key words: Hypertrophic scar, Therapy, Intervention, Cytokines

Background

A hypertrophic scar (HS) is a skin condition characterized by excessive fibrosis with disordered collagens from skin fibroblasts [1]. HS usually develops during the wound healing process subsequent to deep-thickness trauma or burn injury and hinders normal function, resulting in physical, psychological and aesthetic problems for patients [2, 3]. Several clinical studies reported that the incidence rates differed among causes, from 40% to 94% following surgery and from 30% to 91% following burn injury. In low- and middle-income countries, the incidence rate is greater, reflecting the high rate of burn injuries [4]. Major risk factors for HS formation include gender, age, genetic predisposition, immunological responses of the patient, type of injury, wound size and depth, anatomical site and mechanical tension on the wound [5]. Furthermore, previous studies demonstrated that HS proliferate exponentially for 2–18 months after injury [6].

However, the underlying mechanisms of HS development are poorly understood; thus, there are few effective therapies. Noninvasive treatments include intralesional corticosteroid injection and laser, which have not been effective at fully preventing HS formation. Recent studies have investigated whether intralesional injection of botulinum toxin type A (BTXA) was more effective in inhibiting HS than intralesional injection of corticosteroid or placebo [7, 8]. However, these treatments fail to effectively regenerate healthy dermal tissue [9]. Once scar tissues mature, it is impossible for the surrounding tissue to regenerate normal dermal tissue [10–12]. Therefore, the current treatment of HS mainly depends on surgical excision with postoperative radiation, which is invasive [13]. It is essential to understand the fundamental mechanisms and establish effective strategies to inhibit aberrant scar formation.

The purpose of this review was to outline the management in the early stage after wound healing to prevent HS formation, focusing

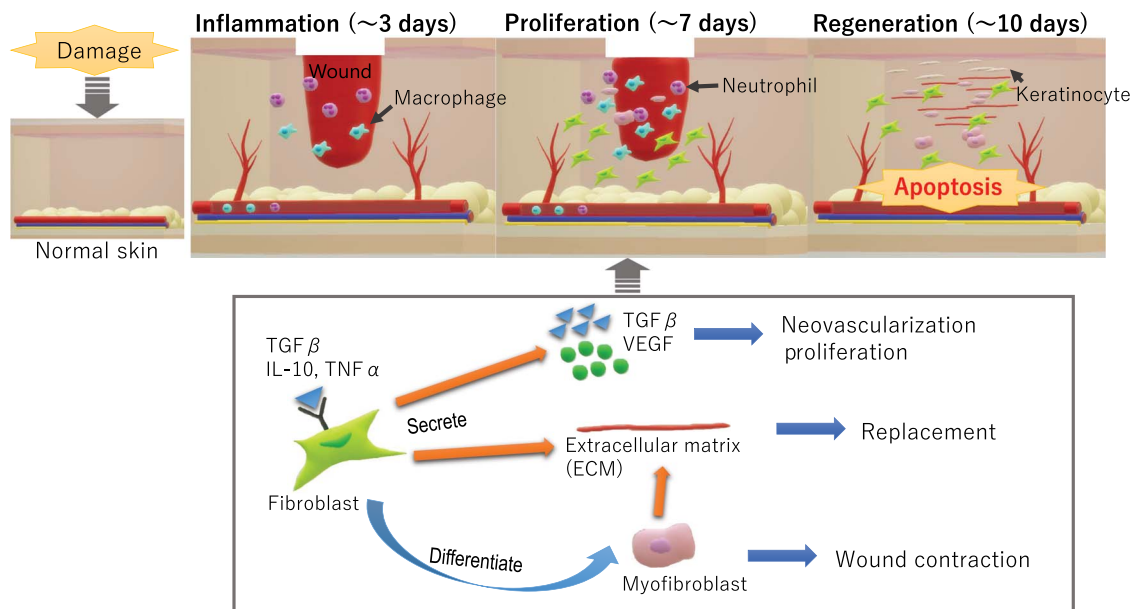


Figure 1. Wound healing mechanism. An abnormality within the processes can cause HS formation. HS hypertrophic scar, TGF β transforming growth factor beta, VEGF vascular endothelial growth factor, IL interleukin, TNF tumor necrosis factor

on strategies excluding therapeutic agents of internal use. We suggest the potential of numerous therapies for treating wounds expected to develop into HS after burn, trauma, or surgery.

Review

Wound healing and scarring

Skin wound healing is a process that consists of three sequential phases: inflammation, proliferation and regeneration. HS formation can occur as a result of an abnormality in these processes. When skin is deeply injured, the early inflammatory cascade will be activated, in which numerous inflammatory cells infiltrate the damaged area and release cytokines [14]. The cytokines stimulate the migration of keratinocytes and fibroblasts to the wound site, and subsequent proliferation of these cells begins 4–5 days later. Fibroblasts secrete extracellular matrix (ECM) proteins such as fibronectin, collagen and hyaluronic acid, resulting in the formation of granulation tissue [1]. During the proliferation phase, abundant vascularization and angiogenesis play a key role in supplying the inflammatory cells and fibroblasts for the formation of an occasional granulation matrix [15]. It is well known that increased vascular density is present in hypertrophic scars compared with normal scars [16]. Approximately 1 week after sustaining the wound, some fibroblasts differentiate into myofibroblasts that also secrete ECM proteins, including collagen 1 and 3. Myofibroblasts are alpha-smooth muscle actin (α -SMA)-positive cells which are activated by transforming growth factor- β 1 (TGF- β 1). They play a key role in contracting the edges of the wound and reducing wound size [17, 18]. Simultaneously, re-epithelization begins as keratinocytes proliferate at the wound margin. When the re-epithelization is initiated, the number of blood vessels is decreased, which induces apoptosis in both fibroblasts and myofibroblasts. As a result, wound contraction is discontinued [17]. Therefore, there are few fibroblasts in mature scar tissue (Fig. 1).

HS formation is considered a result of the imbalance between ECM synthesis and degradation during wound healing [19]. How-

ever, the excessive inflammatory cytokines, including IL-1 β , IL-6 and TNF- α , not only promote fibroblast proliferation and ECM synthesis, but also inhibit collagenase activity and increase the production of collagenase inhibitors. These events result in abnormal collagen composition and ultimately lead to scarring [14]. It is widely accepted that the time to complete wound healing is the most important factor to predict the development of HS. Past studies regarding burn patients reported that only one-third of wounds developed scarring tissue if healing occurred between 14 and 21 days. On the other hand, 78% of the sites became HS if the wound healed after 21 days [20]. Treatments always have some controversy, especially for burn patients. It is difficult to assess the depth and range of a burn, and to reach agreement on post-surgery management [21]. During the wound-healing process, any abnormality can have a negative influence on tissue regeneration and lead to HS formation. From a preventive perspective, some therapeutic interventions should be recommended for patients in whom wound healing takes longer than 14 days for wound closure (Fig. 2).

Signaling pathway in fibroblasts of HS

Transforming growth factor beta (TGF β) is the most representative cytokine to promote fibrosis and scarring formation. It is secreted by numerous cells, mainly activated T cells, macrophages, neutrophils and platelets [22]. Chen et al. found that the expression of TGF β 1 is increased in HS [23]. The topical application of TGF β 1 inhibitor within 2 weeks after injury resulted in clinical improvement in terms of scar maturation [22]. Moreover, several studies have demonstrated the influence of cell proliferation by TGF β 1, with the underlying mechanism mainly comprising the regulation of Smad3 by TGF β 1 [24, 25].

Numerous signaling transduction pathways participate in inducing cell proliferation and inhibiting cell apoptosis, which mediate the formation and promotion of HS (Fig. 2). Among them, the TGF β 1/Smad pathway is considered to play an important role in HS formation by mainly promoting two functions:

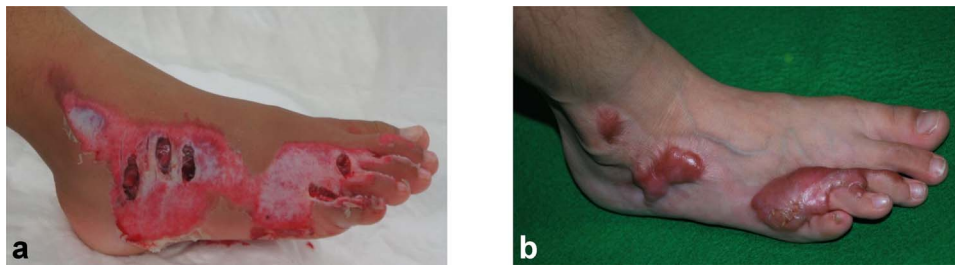


Figure 2. A five-year-old girl sustained an avulsion injury on dorsal foot. (a) Conservative treatment was continued for 40 days. (b) One year after the wound healed, hypertrophic scars are observed at the deep wound

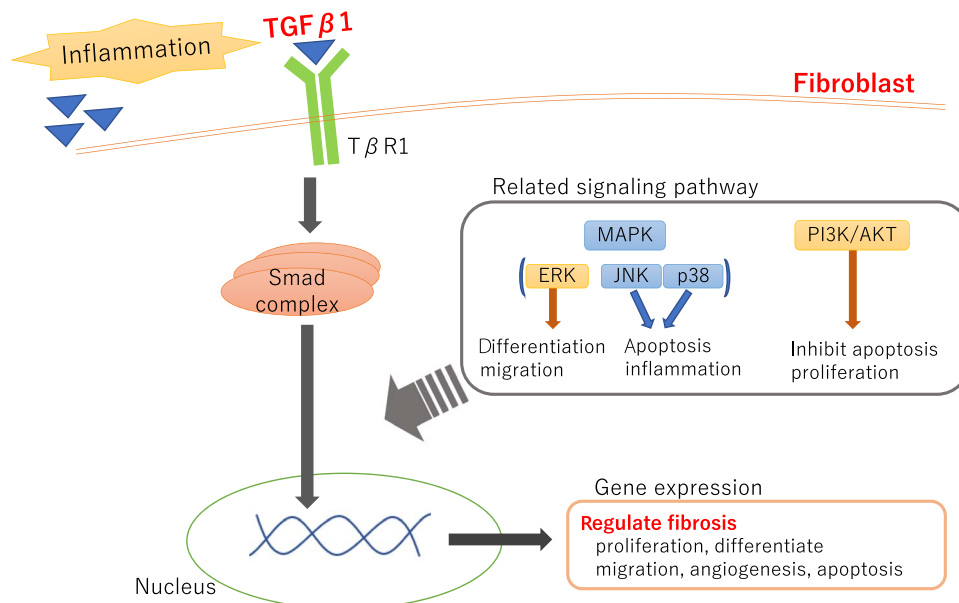


Figure 3. TGF β 1/Smad signaling pathway in fibroblast. TGF β transforming growth factor beta, MAPK mitogen-activated protein kinase, PI3K/AKT phosphoinositide 3 kinase/protein kinase B, ERK extracellular signal-regulated protein kinase, JNK c-Jun N-terminal kinase

ECM synthesis or deposition by stimulating fibroblasts and the induction of fibroblast differentiation into myofibroblasts [26–28]. The mitogen-activated protein kinase (MAPK) and phosphoinositide 3 kinase/protein kinase B (PI3K/AKT) pathways are also the two major representative signaling pathways. MAPKs, including the extracellular signal-regulated protein kinase (ERK), c-Jun N-terminal kinase (JNK) and p38 pathways promote the TGF- β 1/Smad signal pathway in scarring fibroblasts [27]. However, the specific molecular target drug has not been clinically applied for HS. We collected diverse reports of novel treatments for abnormal scarring. Most therapeutic options have potential effectiveness as both monotherapy and combination therapy for the management of abnormal scarring (Fig. 3).

Current and emerging approaches to HS

Pressure therapy Pressure treatment has been considered the mainstay noninvasive treatment for HS, and is widely used worldwide and its effectiveness has been established [4, 29]. According to the study using the Bama minipig model, 1- to 2-month pressure application inactivated the PI3K/AKT pathways and activated the ERK signaling pathways, leading to downregulation of the mRNA expression of collagen I and III analyzed by quantitative polymerase chain reaction (q-PCR) compared with no-pressure conditions. In

addition, the pressure intervention resulted in a smaller size, less contraction and softer scar surface [30]. These results were considered to be due to the restriction of blood flow to the scar tissue, leading to a low supply of oxygen, nutrients and cytokines involved in the inflammatory response. Ischemia induces mitochondria swelling and vacuolation, causing fibroblasts to reduce their ability to synthesize ECM. Additionally, hypoxic environments induce the release of prostaglandin E₂, which increases the expression of collagenase, thereby degenerating collagen fibers [31]. In brief, it is possible that pressure intervention in the early stage of HS formation helps to regulate neovascularization and reduce inflammation in the scar area. A previous study suggested that it is more effective if pressure therapy is performed within 2 months after injury [32]. The authors recommended that the pressure should be maintained between 20 and 30 mmHg, which is above capillary pressure. However, high pressures exceeding 30–40 mmHg can cause severe adverse events, including maceration or paresthesia at the area [33–36].

Silicone The mechanism of treatment using silicone-based products is considered to restore the barrier function of the stratum corneum by reducing transepidermal water loss (TEWL). Once the function of the stratum corneum is disrupted by deep-thickness wounds, the TEWL will increase and take more than 1 year to normalize [37]. An

in-vitro study demonstrated that the levels of proinflammatory cytokine mRNAs increased in cultured keratinocytes exposed to dehydration [38]. These cytokines affect the signaling pathway involved in the production of collagen by fibroblasts. Moreover, clinical trials and cases reported that keratinocytes stop producing cytokines after 2–3 months of silicone gel treatment [39]. This review suggests that the mechanism of action of silicone therapy has not been completely determined, but is likely to involve the occlusion and hydration of the stratum corneum with subsequent cytokine-mediated signaling from keratinocytes to dermal fibroblasts. On the other hand, Phillips et al. reported that the treatment of HS with a moisturizer had no effect on scar elevation or erythema [40]. Overall, these outcomes suggest that intervention by simple hydration is insufficient for reducing abnormal scarring.

Steroids The topical administration of steroids for burn injuries has generally been used. Glucocorticoids have been reported to be effective in improving dermal microcirculation in an animal study [41]. In addition, it has been reported that glucocorticoids protect against TNF- α -induced apoptosis of fibroblast cells in mice [42, 43]. Recently, Sobec et al. reported that the topical administration of oxandrolone, which is an anabolic steroid with less virilization potential than testosterone, led to better wound healing and reduced HS formation in rabbit ears [44]. The epidermis is highly sensitive to injury and plays a key role, not only in inflammation initiation, but also in maintaining inflammation long after re-epithelization [45].

As prolonged inflammation induces HS formation, topical steroids are a good option. In another clinical study, children with severe burns (>40% total body surface area) received oxandrolone daily for almost 1 year, leading to a reduction of acute-phase inflammatory proteins without hepatotoxicity, which is sometimes described as an adverse event of the systemic administration of oxandrolone [46–49].

Laser therapy There is consistent evidence that early laser intervention for the prevention of HS formation would be beneficial in both the speed of scar reduction and the efficacy of therapeutic response. Clinically, it has been widely accepted that pulsed dye laser (PDL) treatment reduces HS formation mainly by decreasing angiogenesis. PDL has been reported to improve the pliability and erythema of immature scar by destruction of small blood vessels by photothermolysis [50]. Other theories of the mechanism by which PDL may achieve clinical efficacy in the treatment of scars include the decreased cellular activity resultant from laser-induced anoxia or through collagenolysis by laser stimulation of cytokine release [51]. Brewin and Lister. described the effectiveness of early intervention using PDL for HS [2]. They suggested that success would be shown when 2–3 treatments have been performed at intervals of around 6 weeks within 6 months after injury. The most common side effect of PDL is post-delivery purpura, which persists up to 7–10 days. However, few serious side effects of the use of PDL have been reported [52]. We should consider actively early PDL intervention because it is less invasive.

Recently, the use of ablative lasers based on the fractional approach has become a novel strategy for the treatment of scars [53, 54]. The detailed mechanism by which the fractional laser affects scar remodeling is unknown, but ablative fractional resurfacing may influence the secretion of various cytokines and growth factors. Qu et al. showed that fractional carbon oxide (CO₂) laser treatment induced mature hypertrophic burn scar regression by suppressing

both types I and III collagen deposition through decreasing TGF β 2, TGF β 3 and basic fibroblast growth factor expression and increasing matrix metalloproteinases-1 expression [55]. Their findings indicated that these factors may play an important role in the regression of mature HS following fractional CO₂ laser treatment. Rodriguez et al. have developed a model of third-degree dermal burn injury in Red Duroc pigs to compare the effects of CO₂ and erbium:yttrium–aluminum–garnet (Er:YAG) ablative fractional lasers in the treatment of HS following acute burn injury [56]. In their work, molecular changes noted in the areas of dermal remodeling indicated that matrix metalloproteinase (MMP)-2, MMP-9 and decorin (DCN) play significant roles in tissue regeneration and account for the enhanced effect of the Er:YAG laser treatment. Further animal or prospective studies are needed to determine how fractional laser treatment induces biosignals that suppress HS formation.

Resection and radiation as adjuvant therapy Surgical approaches vary with the type of scar. In the case of keloids, simple surgical excision leads to faster synthesis of new ECM and results in larger scarring. Thus, high recurrence rates between 50% and 80% have been reported [57]. Mechanical tension placed on the wound or scar promotes angiogenesis and induces scarring [58]. To prevent the recurrence of keloids, surgical excision using postoperative radiation within 48 hr is widely accepted [59–61]. In an established scar, the cells no longer rapidly proliferate and the ECM is already laid down. This is why radiotherapy alone is not effective. In contrast, the inflammatory cells that infiltrate during initial surgical wound healing are radiosensitive and largely eliminated by apoptosis. As a result of inflammatory reduction, radiation therapy as an adjuvant treatment can prevent the occurrence of abnormal scarring by controlling fibroblast proliferation and arresting the cell cycle [62]. Clinically, the appropriate protection of surrounding tissue is essential to avoid radiation-induced carcinogenesis or other side effects. Electron beams, which can achieve high homogeneity at the required depth without irradiation of the deeper structures, are mainly used [63].

At this point, extra- or intralesional excision of hypertrophic scars followed by early postoperative radiotherapy should be both simple and effective at preventing recurrence at excision sites. However, we need long-term results including carcinogenesis to apply it as a reliable medical intervention.

Botulinum toxin type A BTXA is a neurotoxic protein produced by the bacterium *Clostridium botulinum* or related species. It has been used to treat hyperhidrosis and cervical dystonia, so its safety and efficacy have been established [64]. Recently, BTXA has been used in the treatment of HS by injecting it into the musculature underlying wound sites and this has achieved good outcomes, reducing the itching, promoting scar softening and reducing the effects of contracture [65–67]. Jeong et al. reported that fibroblast-to-myofibroblast differentiation was significantly decreased after BTXA treatment of fibroblasts from hypertrophic scars [68]. Xiao et al. also demonstrated that BTXA effectively inhibited fibroblasts from proliferation and differentiation into myofibroblasts, which can regulate the expression of TGF β 1 and ECM proteins [69].

Although BTXA has inhibitory effects on ‘fibroblasts in the aberrant scar’, it demonstrated no significant inhibitory effects on ‘fibroblasts in the normal scar’ even when the concentration was increased [70]. However, the optimal concentration of BTXA as an intralesional injection is unknown and may depend

Table 1. Mechanisms of interventions in this review.

| | Antifibroblast | Anti-inflammation | Anti-angiogenesis | Reference |
|-----------|--|--|------------------------------------|-------------|
| Pressure | Hypoxia (inhibit ability to synthesize collagen, accelerate apoptosis) | Low supplication cells and cytokines | Restrict blood flow | [30–32] |
| Silicon | | Reduce TEWL (reduce cytokine from keratinocytes) | | [37, 38] |
| Steroid | Protect against TNF- α -induced apoptosis of fibroblast | Reduce inflammation | | [42–45] |
| Laser | Anoxia | | Destruction of small blood vessels | [50, 51] |
| Radiation | inhibit fibroblasts proliferation, induce cellular senescence | Promote immune cell apoptosis | | [62] |
| BTXA | decrease TGF- β 1 expression (inhibit fibroblasts proliferation and differentiation) | | | [69] |
| ADSC | Reduce NO (inhibit fibroblasts proliferation and differentiation) Increase DCN (reduce TGF- β 1 activity) | Inflammatory regulation | | [87, 90–92] |

TNF tumor necrosis factor, TGF β transforming growth factor beta, BTXA botulinum toxin type A, ADSC adipose-derived stem cells, DCN decorin, TEWL transepidermal water loss, NO nitric oxide

on the size or severity of the wound. We conclude that the injection of BTXA for HS is promising and worth investigating further.

Future management possibilities for HS

Anti-inflammatory therapy Both clinical cases and experimental studies have demonstrated that HS is due to delayed wound healing. As persistent inflammation of the injured skin may lead to HS formation, anti-inflammatory therapy will be an effective strategy to avoid it. Interleukin 10 (IL-10) is considered to play a key role in scar formation by regulatory actions against the recruitment and differentiation of inflammatory cells [71]. IL-10 also has antifibrotic effects by activating the crosstalk between PI3K/AKT and Janus kinase/signal transducers and activators of transcription3 (JAK/STAT3) signaling pathways in fibroblasts stimulated by TGF- β -1. This is why IL-10 downregulates the collagen expression in fibroblasts, leading to the attenuation of fibrosis [72,73].

Tumor necrosis factor alpha stimulated gene 6 (TSG-6) was identified from cDNA from TNF-treated fibroblasts. It belongs to the hyaluronic acid binding protein family [74]. TSG-6 inhibits the expression of the inflammatory cytokines, including IL-6, IL-1 β and TNF- α , and reduces angiogenesis, resulting in fibroblast apoptosis. TSG-6 is a protein that has both anti-inflammatory effects and proapoptosis effects; therefore, the injection of TSG-6 into scar tissue may be effective to reduce the deposition of collagen [14].

Anti-angiogenesis therapy HS tissues contain more microvessels than the normal dermis [75]. There have been several experimental investigations on the effectiveness of anti-angiogenic therapy to reduce abnormal tissue formation [76, 77]. Some studies described that an antivascular endothelial growth factor (VEGF) monoclonal antibody effectively inhibited not only angiogenesis in scar tissues, but also ECM production from the fibroblasts in mice [78, 79].

Ursolic acid (UA) is an active compound isolated mainly from lichens [80]. Previous studies using the rabbit ear model revealed that UA attenuated HS formation and the effects were associated with suppression of the VEGFR2-mediated signaling pathway [81]. In-vitro investigations suggested that UA suppresses the proliferation,

migration and tube formation of endothelial cells [80]. Based on these principles, anti-angiogenesis therapy may be an efficient and feasible approach.

Adipose-derived cell therapy A relatively new option for preventing HS is autologous fat grafting, resulting in partial but significant improvements in abnormal scar tissue [82]. Klinger et al. reported a clinical assessment using the Patient and Observer Scar Assessment Scale (POSAS) and durometer measurements in 20 patients with HS [83]. The clinical trial revealed that areas treated using autologous fat grafts were significantly reduced. Bruno et al. reported a total of 93 burn scars assessed by histological evaluation [84]. In the study, marked improvement was observed 3 months after undergoing autologous fat transplantation. This mechanism is still under discussion, but the stem cells from adipose tissue may function in such histological and clinical scar improvement.

Numerous studies have reported that adipose tissue is composed of several cell types, including adipocytes, immune cells and adipose-derived stem cells (ADSC), that still retain differentiation potential [85, 86]. ADSCs are abundant in adipose tissue, and can be readily acquired, separated and cultured, hence why they are now widely investigated regarding their ability to promote wound healing. Moreover, ADSCs have an inflammatory regulatory function by secreting different bioactive substances, and are expected to inhibit abnormal scar formation [87–89]. Moreover, based on animal scarring models, the transplantation of ADSCs into scar tissue may be effective at inhibiting fibroblast proliferation and transformation into myofibroblasts by reducing nitric oxide (NO) [90]. A study using a rabbit ear scarring model demonstrated that the p53 protein level was higher in HS tissues than in normal scar tissues. According to previous reports, mesenchymal stem cells (MSC) with p53 gene knockdown lost the ability to reduce the proliferation of fibroblasts through increasing NO production [91]. These findings suggest that the effects of MSC depend on p53-related pathways.

Another recent finding was the role of ADSCs in the prevention and treatment of pathological scars. An immunofluorescence assay revealed that ADSCs can inhibit α -SMA expression and pro-

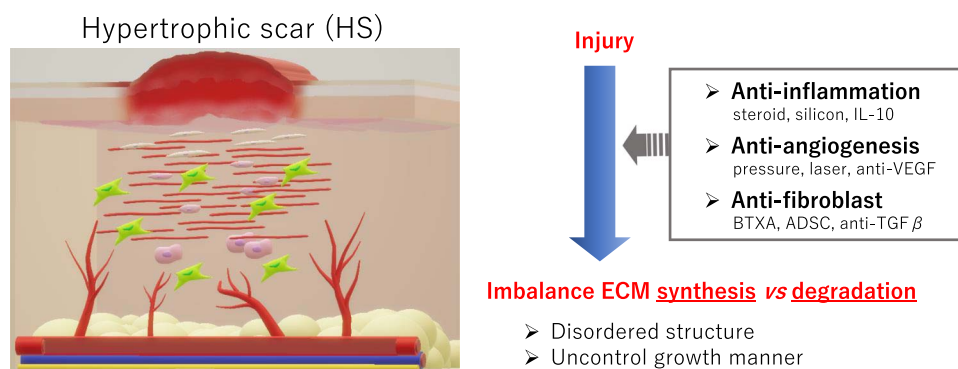


Figure 4. Schema of hypertrophic scar formation. Target of therapeutic intervention. *IL* interleukin, *BTXA* botulinum toxin type A, *ADSC* adipose-derived stem cells, *TGFβ* transforming growth factor beta, *ECM* extracellular matrix

mote DCN expression [10]. DCN is an extracellular small-molecular complex synthesized by fibroblasts. It can bind to $TGF\beta 1$ to reduce its activity and the occurrence of fibrosis [92]. DCN-related therapy is also expected to be used in the prevention and treatment of excessive scar formation [56] (Table 1).

Perspective and limitation

Treatment aimed at molecular targets, including cytokines, will be future options to prevent and treat HS. Recently, targeting drugs blocking the specific signaling pathway have been used in clinical situations. For example, the topical treatment of a JAK inhibitor was applied for atopic dermatitis. Such topical treatment is preferable considering side effects. At this stage, we can summarize and provide some strategies to prevent HS formation (Fig. 4). More basic studies and clinical trials, including combination therapy, are required to investigate the mechanisms and prevent HS formation.

For decades, animal models of HS have been used to reveal the pathophysiology of scarring and test new therapies, such as the rabbit ear model, the white pig model and nude mice. The main limitation of these models was the inability to reproduce the normal process of HS development [93]. Aberrant scars, including HS, are specific to humans. Laboratory animals have a fibromuscular layer under the dermis, which is considered to be the main pathological difference to humans. Therefore, healing from injury depends on wound contraction rather than re-epithelialization in animal models [44]. The rabbit ear model of HS is well-established and widely used for investigations. However, the physiology and immune system of rabbit skin are very different from those of humans. Moreover, genetic predisposition, which plays an important role in HS formation in humans, has not been considered in the rabbit ear model [94].

Conclusion

Acceleration of the wound-healing process can reduce the incidence of HS formation; therefore, proper management and interventions in the early stage of wound healing remain important. We provided some strategies based on molecular evidence to prevent HS formation after wound healing. Further studies that reveal the underlying mechanisms of wound healing and HS formation are needed to provide new treatment options for the management of aberrant scars.

Funding

The authors declare that there are no financial disclosures.

Authors' contributions

ES and SY wrote the review manuscript, and KH revised the article. All authors read and approved the final manuscript.

Ethics approval and consent to participate

Consent for inclusion in the Shimane University Hospital Registry includes the possibility of publication of information for research purposes.

Conflicts of interest

The authors declare that they have no competing interests.

References

- Gauglitz GG, Korting HC, Pavicic T, Ruzicka T, Jeschke MG. Hypertrophic scarring and keloids: Pathomechanisms and current and emerging treatment strategies. *Mol Med.* 2011;17:113–25.
- Brewin MP, Lister TS. Prevention or treatment of hypertrophic burn scarring: A review of when and how to treat with the pulsed dye laser. *Burns.* 2014;40:797–804.
- Shi JH, Guan H, Shi S, Cai W-X, Bai X-Z, Hu X-L, et al. Protection against TGF-beta1-induced fibrosis effects of IL-10 on dermal fibroblasts and its potential therapeutics for the reduction of skin scarring. *Arch Dermatol Res.* 2013;305:341–52.
- Bloemen MC, van der Veer WM, Ulrich MM, van Zuijlen PP, Niessen FB, Middelkoop E. Prevention and curative management of hypertrophic scar formation. *Burns.* 2009;35:463–75.
- Niessen FB, Spauwen PH, Schalkwijk J, Kon M. On the nature of hypertrophic scars and keloids: A review. *Plast Reconstr Surg.* 1999;104:1435–58.
- Oliveira GV, Chinkes D, Mitchell C, Oliveras G, Hawkins HK, Herndon DN. Objective assessment of burn scar vascularity, erythema, pliability, thickness, and planimetry. *Dermatol Surg.* 2005;31:48–58.
- Bi M, Sun P, Li D, Dong Z, Chen Z. Intralesional injection of Botulinum toxin type a compared with intralesional injection of corticosteroid for the treatment of hypertrophic scar and keloid: A systematic review and meta-analysis. *Med Sci Monit.* 2019;25:2950–8.
- Hu L, Zou Y, Chang SJ, Qiu Y, Chen H, Gang M, et al. Effects of Botulinum toxin on improving facial surgical scars: A prospective, split-scar, double-blind, randomized controlled trial. *Plast Reconstr Surg.* 2018;141:646–50.
- Wang J, Liao Y, Xia J, Wang Z, Mo X, Feng J, et al. Mechanical micronization of lipoaspirates for the treatment of hypertrophic scars. *Stem Cell Res Ther.* 2019; 10: 42.

10. Chu H, Wang Y, Wang X, Song X, Liu H, Li X. Effects of transplanted adipose derived stem cells on the expressions of alpha-SMA and DCN in fibroblasts of hypertrophic scar tissues in rabbit ears. *Exp Ther Med*. 2018;16:1729–34.
11. Steintraesser L, Flak E, Witte B, Ring A, Tilkorn D, Hauser J, et al. Pressure garment therapy alone and in combination with silicone for the prevention of hypertrophic scarring: Randomized controlled trial with intraindividual comparison. *Plast Reconstr Surg*. 2011;128:306–13e.
12. Jackson WM, Nesti LJ, Tuan RS. Mesenchymal stem cell therapy for attenuation of scar formation during wound healing. *Stem Cell Res Ther*. 2012;3:20.
13. Ogawa R. Surgery for scar revision and reduction: From primary closure to flap surgery. *Burns Trauma*. 2019;7:7.
14. He B, Wang Y, Shao N, Chang H, Cheng Y. Polymers modified with double-tailed fluoruous compounds for efficient DNA and siRNA delivery. *Acta Biomater*. 2015; 22: 111–9.
15. Brown LF, Yeo KT, Berse B, Yeo TK, Senger DR, Dvorak HF, et al. Expression of vascular permeability factor (vascular endothelial growth factor) by epidermal keratinocytes during wound healing. *J Exp Med*. 1992;176:1375–9.
16. Amadeu T, Braune A, Mandarim-de-Lacerda C, Porto LC, Desmoulière A, Costa A. Vascularization pattern in hypertrophic scars and keloids: A stereological analysis. *Pathol Res Pract*. 2003;199:469–73.
17. Hinz B. The role of myofibroblasts in wound healing. *Curr Res Transl Med*. 2016;64:171–7.
18. Hinz B. The myofibroblast: Paradigm for a mechanically active cell. *J Biomech*. 2010;43:146–55.
19. Spyrou GE, Naylor IL. The effect of basic fibroblast growth factor on scarring. *Br J Plast Surg*. 2002;55:275–82.
20. Placik OJ, Lewis VL, Jr. Immunologic associations of keloids. *Surg Gynecol Obstet*. 1992;175:185–93.
21. Hayashida K, Fujioka M, Morooka S, Saijo H, Akita S. Effectiveness of basic fibroblast growth factor for pediatric hand burns. *J Tissue Viability*. 2016;25:220.
22. Qiu SS, Dotor J, Hontanilla B. Effect of P144(R) (anti-TGF-beta) in an "in vivo" human hypertrophic scar model in nude mice. *PLoS One*. 2015;10:e0144489.
23. Chen Q, Zhao T, Xie X, Yu D, Wu L, Yu W, et al. MicroRNA-663 regulates the proliferation of fibroblasts in hypertrophic scars via transforming growth factor-beta1. *Exp Ther Med*. 2018;16:1311–7.
24. Hong F, Wu N, Ge Y, Zhou Y, Shen T, Qiang Q, et al. Nanosized titanium dioxide resulted in the activation of TGF-beta/Smads/p38MAPK pathway in renal inflammation and fibration of mice. *J Biomed Mater Res A*. 2016;104:1452–61.
25. Zhou B, Zeng S, Li L, Fan Z, Tian W, Li M, et al. Angiogenic factor with G patch and FHA domains 1 (Aggf1) regulates liver fibrosis by modulating TGF-beta signaling. *Biochim Biophys Acta*. 2016;1862:1203–13.
26. Liu J, Wang Y, Pan Q, Su Y, Zhang Z, Han J, et al. Wnt/beta-catenin pathway forms a negative feedback loop during TGF-beta1 induced human normal skin fibroblast-to-myofibroblast transition. *J Dermatol Sci*. 2012;65:38–49.
27. He S, Liu X, Yang Y, Huang W, Xu S, Yang S, et al. Mechanisms of transforming growth factor beta(1)/Smad signalling mediated by mitogen-activated protein kinase pathways in keloid fibroblasts. *Br J Dermatol*. 2010;162:538–46.
28. He T, Bai X, Yang L, Fan L, Li Y, Su L, et al. Loureirin B inhibits hypertrophic scar formation via inhibition of the TGF-beta1-ERK/JNK pathway. *Cell Physiol Biochem*. 2015;37:666–76.
29. Bailey AJ, Bazin S, Sims TJ, Le Lous M, Nicoletis C, Delaunay A. Characterization of the collagen of human hypertrophic and normal scars. *Biochim Biophys Acta*. 1975;405:412–21.
30. Liu B, Liu Y, Wang L, Hou C, An M. The effects of pressure intervention on wound healing and scar formation in a Bama minipig model. *Burns*. 2019;45:413–22.
31. Reno F, Grazianetti P, Cannas M. Effects of mechanical compression on hypertrophic scars: Prostaglandin E2 release. *Burns*. 2001;27:215–8.
32. Li P, Li-Tsang CWP, Deng X, Wang X, Wang H, Zhang Y, et al. The recovery of post-burn hypertrophic scar in a monitored pressure therapy intervention programme and the timing of intervention. *Burns*. 2018;44:1451–67.
33. Stella M, Castagnoli C, Gangemi EN. Postburn scars: An update. *Int J Low Extrem Wounds*. 2008;7:176–81.
34. Oliveira GV, Hawkins HK, Chinkes D, Burke A, Tavares AK, Ramos-Silva M, et al. Hypertrophic versus non hypertrophic scars compared by immunohistochemistry and laser confocal microscopy: Type I and III collagens. *Int Wound J*. 2009;6:445–52.
35. Ahmad A, Herndon DN, Szabo C. Oxandrolone protects against the development of multiorgan failure, modulates the systemic inflammatory response and promotes wound healing during burn injury. *Burns*. 2019;45:671–81.
36. Cho YS, Jeon JH, Hong A, Yang HT, Yim H, Cho YS, et al. The effect of burn rehabilitation massage therapy on hypertrophic scar after burn: A randomized controlled trial. *Burns*. 2014;40:1513–20.
37. Suetake T, Sasai S, Zhen YX, Ohi T, Ogami H. Functional analyses of the stratum corneum in scars. Sequential studies after injury and comparison among keloids, hypertrophic scars, and atrophic scars. *Arch Dermatol*. 1996;132:1453–8.
38. Terunuma A, Aiba S, Tagami H. Cytokine mRNA profiles in cultured human skin component cells exposed to various chemicals: A simulation model of epicutaneous stimuli induced by skin barrier perturbation in comparison with that due to exposure to haptens or irritant. *J Dermatol Sci*. 2001;26:85–93.
39. Mustoe TA. Evolution of silicone therapy and mechanism of action in scar management. *Aesthetic Plast Surg*. 2008;32:82–92.
40. Phillips TJ, Gerstein AD, Lordan V. A randomized controlled trial of hydrocolloid dressing in the treatment of hypertrophic scars and keloids. *Dermatol Surg*. 1996;22:775–8.
41. Robson MC, Kucan JO, Paik KI, Eriksson E. Prevention of dermal ischemia after thermal injury. *Arch Surg*. 1978;113:621.
42. Kull FC, Jr. Reduction in tumor necrosis factor receptor affinity and cytotoxicity by glucocorticoids. *Biochem Biophys Res Commun*. 1988;153:402–9.
43. Costas M, Trapp T, Pereda MP, Sauer J, Rupprecht R, Nahmod VE, et al. Molecular and functional evidence for in vitro cytokine enhancement of human and murine target cell sensitivity to glucocorticoids. TNF-alpha priming increases glucocorticoid inhibition of TNF-alpha-induced cytotoxicity/apoptosis. *J Clin Invest*. 1996;98:1409–16.
44. Sobec RL, Fodor L, Bodog F. Topical Oxandrolone reduces ear hypertrophic scar formation in rabbits. *Plast Reconstr Surg*. 2019;143:481–7.
45. Mustoe TA, Gurjala A. The role of the epidermis and the mechanism of action of occlusive dressings in scarring. *Wound Repair Regen*. 2011;19(Suppl 1):s16–21.
46. Thomas S, Wolf SE, Murphy KD, Chinkes DL, Herndon DN. The long-term effect of oxandrolone on hepatic acute phase proteins in severely burned children. *J Trauma*. 2004;56:37–44.
47. Grunfeld C, Kotler DP, Dobs A, Glesby M, Bhasin S. Oxandrolone in the treatment of HIV-associated weight loss in men: A randomized, double-blind, placebo-controlled study. *J Acquir Immune Defic Syndr*. 2006;41:304–14.
48. Orr R, Fiatarone Singh M. The anabolic androgenic steroid oxandrolone in the treatment of wasting and catabolic disorders: Review of efficacy and safety. *Drugs*. 2004;64:725–50.
49. Li H, Guo Y, Yang Z, Roy M, Guo Q. The efficacy and safety of oxandrolone treatment for patients with severe burns: A systematic review and meta-analysis. *Burns*. 2016;42:717–27.
50. Alster TS, Nanni CA. Pulsed dye laser treatment of hypertrophic burn scars. *Plast Reconstr Surg*. 1998;102:2190–5.
51. Dierickx CC, Casparian JM, Venugopalan V, Farinelli A, Anderson RR. Thermal relaxation of port-wine stain vessels probed in vivo: The need for 1–10-millisecond laser pulse treatment. *J Invest Dermatol*. 1995;105:709–14.

52. Clayton JL, Edkins R, Cairns BA, Hultman CS. Incidence and management of adverse events after the use of laser therapies for the treatment of hypertrophic burn scars. *Ann Plast Surg.* 2013;70(5):500.
53. Jung JY, Jeong JJ, Roh HJ, Cho SH, Chung KY, Lee WJ, et al. Early postoperative treatment of thyroidectomy scars using a fractional carbon dioxide laser. *Dermatol Surg.* 2011;37:217–23.
54. Kim SG, Kim EY, Kim YJ, Lee SI. The efficacy and safety of ablative fractional resurfacing using a 2,940-nm Er:YAG laser for traumatic scars in the early posttraumatic period. *Arch Plast Surg.* 2012;39:232–7.
55. Qu L, Liu A, Zhou L, He C, Grossman PH, Moy RL, et al. Clinical and molecular effects on mature burn scars after treatment with a fractional CO₂ laser. *Lasers Surg Med.* 2012;44:517–24.
56. Rodriguez-Menocal L, Davis SS, Becerra S, Salgado M, Gill J, Valdes J, et al. Assessment of ablative fractional CO₂ laser and Er:YAG laser to treat hypertrophic scars in a red Duroc pig model. *J Burn Care Res.* 2018;39:954–62.
57. Sruthi K, Chelakkot PG, Madhavan R, Nair RR, Dinesh M. Single-fraction radiation: A promising adjuvant therapy to prevent keloid recurrence. *J Cancer Res Ther.* 2018;14:1251–5.
58. Ogawa R, Akaishi S. Endothelial dysfunction may play a key role in keloid and hypertrophic scar pathogenesis – Keloids and hypertrophic scars may be vascular disorders. *Med Hypotheses.* 2016;96:51–60.
59. van de Kar AL, Kreulen M, van Zuijlen PP, Oldenburger F. The results of surgical excision and adjuvant irradiation for therapy-resistant keloids: A prospective clinical outcome study. *Plast Reconstr Surg.* 2007;119:2248–54.
60. Xu J, Yang E, Yu NZ, Long X. Radiation therapy in keloids treatment: History, strategy, effectiveness, and complication. *Chin Med J (Engl).* 2017;130:1715–21.
61. Renz P, Hasan S, Gresswell S, Hajjar RT, Trombetta M, Fontanesi J. Dose effect in adjuvant radiation therapy for the treatment of resected keloids. *Int J Radiat Oncol Biol Phys.* 2018;102:149–54.
62. Ji J, Tian Y, Zhu YQ, Zhang LY, Ji SJ, Huan J, et al. Ionizing irradiation inhibits keloid fibroblast cell proliferation and induces premature cellular senescence. *J Dermatol.* 2015;42:56–63.
63. Guix B. Radiotherapy concepts for keloids current options and clinical results. *Radiother Oncol.* 2004;71:15.
64. Setler PE. Therapeutic use of botulinum toxins: Background and history. *Clin J Pain.* 2002;18:119–24.
65. Gassner HG, Sherris DA. Chemoimmobilization: Improving predictability in the treatment of facial scars. *Plast Reconstr Surg.* 2003;112:1464–6.
66. Omranifard M, Heidari M, Farajzadegan Z, Niktabar MR, Motamedi N. Botulinum toxin and burn induces contracture. *Arch Plast Surg.* 2016;43:609–11.
67. Wilson AM. Use of botulinum toxin type a to prevent widening of facial scars. *Plast Reconstr Surg.* 2006;117:1758–66, discussion 67–8.
68. Jeong HS, Lee BH, Sung HM, Park SY, Ahn DK, Jung MS, et al. Effect of Botulinum toxin type a on differentiation of fibroblasts derived from scar tissue. *Plast Reconstr Surg.* 2015;136:171e–8e.
69. Xiao Z, Zhang F, Lin W, Zhang M, Liu Y. Effect of botulinum toxin type a on transforming growth factor beta1 in fibroblasts derived from hypertrophic scar: A preliminary report. *Aesthetic Plast Surg.* 2010;34:424–7.
70. Hao R, Li Z, Chen X, Ye W. Efficacy and possible mechanisms of Botulinum toxin type a on hypertrophic scarring. *J Cosmet Dermatol.* 2018;17:340–6.
71. Shi J, Li J, Guan H, Cai W, Bai X, Fang X, et al. Anti-fibrotic actions of interleukin-10 against hypertrophic scarring by activation of PI3K/AKT and STAT3 signaling pathways in scar-forming fibroblasts. *PLoS One.* 2014;9:e98228.
72. Sabat R, Grutz G, Warszawska K, Kirsch S, Witte E, Wolk K, et al. Biology of interleukin-10. *Cytokine Growth Factor Rev.* 2010;21:331–44.
73. Glocker EO, Kotlarz D, Klein C, Shah N, Grimbacher B. IL-10 and IL-10 receptor defects in humans. *Ann N Y Acad Sci.* 2011;1246:102–7.
74. Lee TH, Lee GW, Ziff EB, Vilcek J. Isolation and characterization of eight tumor necrosis factor-induced gene sequences from human fibroblasts. *Mol Cell Biol.* 1990;10:1982–8.
75. Zheng J, Song F, Lu SL, Wang XQ. Dynamic hypoxia in scar tissue during human hypertrophic scar progression. *Dermatol Surg.* 2014;40:511–8.
76. Wang P, Jiang LZ, Xue B. Recombinant human endostatin reduces hypertrophic scar formation in rabbit ear model through down-regulation of VEGF and TIMP-1. *Afr Health Sci.* 2016;16:542–53.
77. Kwak DH, Bae TH, Kim WS, Kim HK. Anti-vascular endothelial growth factor (Bevacizumab) therapy reduces hypertrophic scar formation in a rabbit ear wounding model. *Arch Plast Surg.* 2016;43:491–7.
78. Shen R, Li TZ, Qi SH, Liang HZ, Xu YB, Xie JL, et al. A research of endothelial cell-targeted therapy for cure of hypertrophic scar. *Zhonghua Zheng Xing Wai Ke Za Zhi.* 2003;19:254–7.
79. Yue YG, Jiang CW, Li PY, Zhou S. Influence of the VEGF antibody targeted vascular therapy on the expression of collagen type I in hyperplastic. *Zhonghua Shao Shang Za Zhi.* 2006;22:427–30.
80. Song Y, Yu Z, Song B, Gui S, Lei L, Ma X, et al. Usnic acid inhibits hypertrophic scarring in a rabbit ear model by suppressing scar tissue angiogenesis. *Biomed Pharmacother.* 2018;108:524–30.
81. Song Y, Dai F, Zhai D, Dong Y, Zhang J, Lu B, et al. Usnic acid inhibits breast tumor angiogenesis and growth by suppressing VEGFR2-mediated AKT and ERK1/2 signaling pathways. *Angiogenesis.* 2012;15:421–32.
82. Hoerst K, van den Broek L, Sachse C, Klein O, von Fritschen U, Gibbs S, et al. Regenerative potential of adipocytes in hypertrophic scars is mediated by myofibroblast reprogramming. *J Mol Med (Berl).* 2019;97:761–75.
83. Klinger M, Caviggioli F, Klinger FM, Giannasi S, Bandi V, Banzatti B, et al. Autologous fat graft in scar treatment. *J Craniofac Surg.* 2013;24(5):1610.
84. Bruno A, Delli Santi G, Fasciani L, Ceimpanari M, Palombo M, Palombo P. Burn scar lipofilling: Immunohistochemical and clinical outcomes. *J Craniofac Surg.* 2013;24:1806–14.
85. Wang G, Ren Y, Cao W, Yang Y, Li S. Liposculpture and fat grafting for aesthetic correction of the gluteal concave deformity associated with multiple intragluteal injection of penicillin in childhood. *Aesthetic Plast Surg.* 2013;37:39–45.
86. Zuk PA, Zhu M, Ashjian P, De Ugarte DA, Huang JI, Mizuno H, et al. Human adipose tissue is a source of multipotent stem cells. *Mol Biol Cell.* 2002;13:4279–95.
87. Zhang Q, Liu LN, Yong Q, Deng JC, Cao WG. Intralesional injection of adipose-derived stem cells reduces hypertrophic scarring in a rabbit ear model. *Stem Cell Res Ther.* 2015;6:145.
88. Klinger M, Marazzi M, Vigo D, Torre M. Fat injection for cases of severe burn outcomes: A new perspective of scar remodeling and reduction. *Aesthetic Plast Surg.* 2008;32:465–9.
89. Guisantes E, Fontdevila J, Rodriguez G. Autologous fat grafting for correction of unaesthetic scars. *Ann Plast Surg.* 2012;69:550–4.
90. Ferrini MG, Vernet D, Magee TR, Shahed A, Qian A, Rajfer J, et al. Antifibrotic role of inducible nitric oxide synthase. *Nitric Oxide.* 2002;6:283–94.
91. Liu YL, Liu WH, Sun J, Hou TJ, Liu YM, Liu HR, et al. Mesenchymal stem cell-mediated suppression of hypertrophic scarring is p53 dependent in a rabbit ear model. *Stem Cell Res Ther.* 2014;5:136.
92. Bi X, Tong C, Dockendorff A, Bancroft L, Gallagher L, Guzman G, et al. Genetic deficiency of decorin causes intestinal tumor formation through disruption of intestinal cell maturation. *Carcinogenesis.* 2008;29:1435–40.
93. Wang J, Ding J, Jiao H, Honardoust D, Momtazi M, Shankowsky HA, et al. Human hypertrophic scar-like nude mouse model: Characterization of the molecular and cellular biology of the scar process. *Wound Repair Regen.* 2011;19:274–85.
94. Nabai L, Ghahary A. Hypertrophic scarring in the rabbit ear: A practical model for studying dermal fibrosis. *Methods Mol Biol.* 2017;1627:81–9.