

## CLINICAL EVALUATION OF TERBUTALINE AS A POTENTIAL AGENT TREATING ANASTOMOTIC LEAKAGE AFTER GASTRIC OPERATION

(terbutaline / anastomotic leakage / exocrine pancreatic secretion)

Haruhiko NAGAMI, Katsuhiko TAMURA and Akira NAKASE

First Department of Surgery, Shimane Medical University  
Izumo 693, Japan

(Received November 7, 1991/Accepted November 6, 1992)

Clinical advantage of terbutaline sulfate (Bricany<sup>®</sup>) was evaluated for four patients with anastomotic leakage after gastric operation. Terbutaline sulfate was administered subcutaneously or intravenously for the purpose of inhibiting exocrine pancreatic secretion during a few weeks just after anastomotic leakage was recognized. After this treatment, the injured anastomosis was completely healed and no surgical treatment was not necessitated in all cases.

In conclusion terbutaline sulfate is useful for anastomotic leakage after gastric operation.

---

Terbutaline sulfate (Bricany<sup>®</sup>) is a  $\beta$ -stimulator, and is clinically used as a bronchial dilator for bronchial asthma. In addition, this substance is a potential agent to inhibit the exocrine pancreatic secretion. Then, we used terbutaline sulfate for the present four patients with anastomotic leakage after gastric operation.

### PATIENTS AND METHODS

Among the patients who underwent total gastrectomy or subtotal gastrectomy for gastric cancer during the

last two years, four patients were encountered anastomotic leakage after the operation. Terbutaline sulfate was subcutaneously or intravenously administered just after leakage was recognized by postoperative barium X-ray study of gastrointestinal series (GIS). The list of the present patients is shown in Table I.

### CASE REPORTS

#### Case 1 :

A 71-year-old woman, who had undergone partial gastrectomy for gastric ulcer 15 years ago, was diagnosed as cancer of the remnant stomach with invasion to transverse colon. In september, 1990, resection of the remnant stomach associated with splenectomy, and partial resection of jejunum and transverse colon were performed. Reconstructive procedure after the resection was performed by Roux-en-Y method. Postoperatively, the body temperature was elevated and on the 4th postoperative day, laboratory data showed a hemoglobin of 10.5 g/dl, white cell count of 12,500/mm<sup>3</sup> (neutrophils 82%), erythrocyte sedimentation rate (ESR) of 75mm/hr. Discharge containing bile and pancreatic juice through the Penrose drain inserted around the Roux-en-Y jejunojejunostomy was recognized. Postoperative upper GIS on the 11th postoperative day revealed a major leakage from the jejunojejunostomy. Immediate treatment was begun by intravenous administration of factor III (FX III) and subcutaneous administration of terbutaline sulfate. The terbutaline sulfate was administered subcutaneously twice a day (0.4mg/day) from the 11th postoperative day to the 34th postoperative day.

After this therapy, volume of the exudate through the Penrose drain and activity of the pancreatic enzyme (amylase and lipase) were gradually decreased in response to administration of terbutaline sulfate. On the 34th postoperative day, upper GIS showed complete healing of anastomotic leakage of Roux-en-Y jejunojejunostomy (Fig I). Daily changes of volume of the exudate and activity of the pancreatic enzyme, laboratory data

case	age	sex	operative findings operative procedure	terbutaline	
				∴ other drugs	
①	71	F	H <sub>2</sub> ,P <sub>0</sub> ,S <sub>2</sub> ,N <sub>1</sub> ,Stage IV total gastrectomy R <sub>2</sub> (major leakage)	0.4mg/day, 23days subcutaneously ∴ factor III	
②	73	F	H <sub>2</sub> ,P <sub>0</sub> ,S <sub>2</sub> ,N <sub>1</sub> ,Stage III total gastrectomy R <sub>2</sub> (major leakage)	0.4mg/day, 14days intravenously ∴ factor III	
③	58	M	H <sub>2</sub> ,P <sub>0</sub> ,S <sub>0</sub> ,N <sub>0</sub> ,Stage I subtotal gastrectomy R <sub>2</sub> (major leakage)	0.2mg/day, 23days subcutaneously ∴ nafamostat mesilate	
④	71	F	H <sub>2</sub> ,P <sub>0</sub> ,S <sub>2</sub> ,N <sub>1</sub> ,Stage III subtotal gastrectomy R <sub>2</sub> (minor leakage)	0.2mg/day, 9days subcutaneously ∴ factor III	

Table I : The list of the cases studied. Age, sex, operative findings, operative procedure, major leakage or minor leakage, method of administration of terbutaline and other drugs are shown.

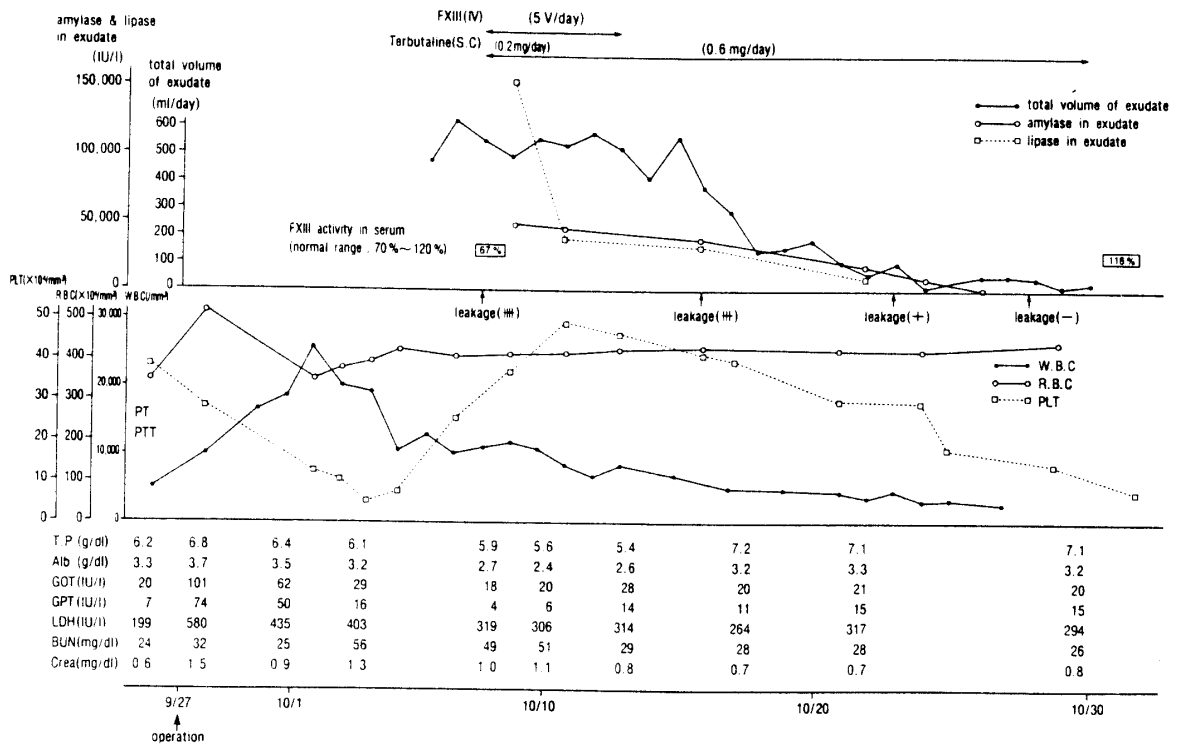


Table II : Changes of volume of the exudate and activity of the pancreatic enzyme, laboratory data and clinical course in case 1.

and clinical course of this patient are shown in Table II.

#### Case 2

A - 73 - year - old woman was diagnosed gastric cancer. In september, 1991, non - curative total gastrectomy was performed and reconstruction was done by Roux - en - Y method. On the 2nd postoperative day, dirty discharge containing intestinal juice through the Penrose drain inserted around the esophagojejunostomy was recognized. Postoperative GIS on the 4th postoperative day showed a major leakage from the esophagojejunostomy. The body temperature was elevated and laboratory data showed white blood cell count of  $13,600/\text{mm}^3$  (neutrophils 78%), and ESR of  $68\text{mm}/\text{hr}$ . Immediate treatment was begun by intravenous administration of FX III and intravenous administration of terbutaline sulfate. The terbutaline sulfate was administered intravenously ( $0.4\text{mg}/\text{day}$ ) by way of continuous drip infusion during 14 days after the 4th postoperative day.

After this treatment, GIS on the 20th postoperative day showed complete healing of anastomotic leakage of esophagojejunostomy (Fig II).

#### Case 3

A - 58 - year - old man was diagnosed as early gastric cancer. In May, 1986, curative subtotal gastrectomy was done and reconstruction was done by gastroduodenostomy (Billroth - I). On the 5th postoperative day, laboratory data showed a hemoglobin of  $10.5\text{g}/\text{dl}$ , white blood cell count of  $15,600/\text{mm}^3$  (neutrophils 90%), and ESR  $86\text{mm}/\text{hr}$ . Dirty discharge through the penrose drain inserted around the gastroduodenostomy was recognized. Postoperative upper GIS on the 6th postoperative day revealed a major leakage from the gastroduodenostomy. Immediate treatment was begun with intravenous administration of nafamostat mesilate and subcutaneous administration of terbutaline sulfate. The terbutaline sulfate was administered once a day during 23 days after the 10th postoperative day.

After this treatment, postoperative upper GIS on the 33th postoperative day showed complete healing

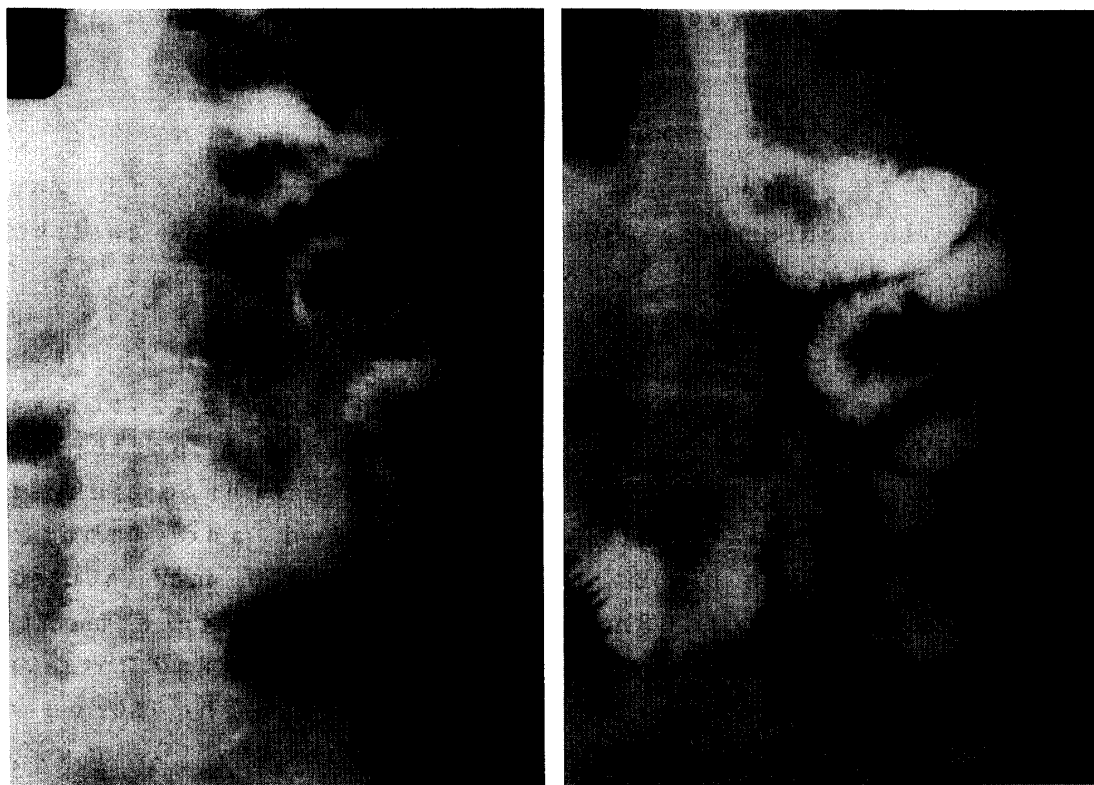


Fig 1 : Postoperative barium X-ray study of gastrointestinal series (GIS) before and after administration of terbutaline in case 1. GIS on the 11th postoperative day revealed a major leakage (↑) from the jejunojejunostomy (left panel). After treatment, GIS on the 34th day showed complete healing of anastomotic leakage (right panel).

of anastomotic leakage of gastroduodenostomy.

#### Case 4

A - 71 - year - old man was diagnosed as advanced gastric cancer. In March, 1991, curative subtotal gastrectomy was performed, and then reconstruction was done by gastroduodenostomy (Billroth - I). Postoperative upper GIS on the 7th postoperative day showed a minor leakage from the gastroduodenostomy. Immediate treatment was begun with intravenous administration of FX III and subcutaneous administration of terbutaline sulfate.

The terbutaline sulfate was administered subcutaneously once a day (0.2mg/day) during 23 days after the 10th postoperative day.

After this treatment, postoperative upper GIS on the 20th postoperative day showed complete healing of anastomotic leakage of gastroduodenostomy.

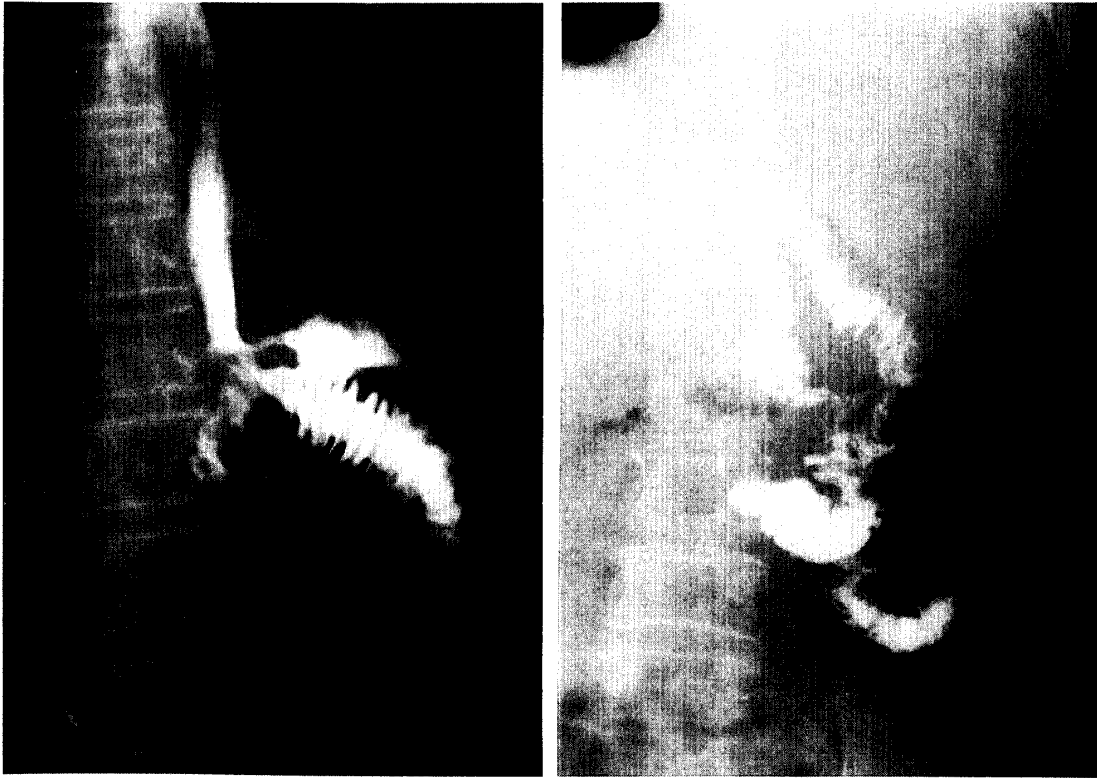


Fig II : GIS before and after administration of terbutaline in case 2. GIS on the 4th postoperative day revealed a major leakage (↑) from the esophagojejunostomy (left panel). After treatment, GIS on the 20th postoperative day showed complete healing of anastomotic leakage (right panel).

## DISCUSSION

Anastomotic leakage of the gastroduodenostomy or esophagojejunostomy is undesirable after gastric operation. For the injured anastomosis, surgical treatment or conservative treatment using potential agents to promote healing of the wound of the anastomosis must be performed, because intestinal juice containing activated pancreatic enzyme should impair healing process of the injured anastomosis. Inhibition of the exocrine pancreatic function or inactivation of the pancreatic

enzymes are useful for the injured anastomosis.

Several investigators have reported the inhibitory effects of atropine, acetazolamide, ephedrine, epinephrine and glucagon on the human pancreatic secretion (1-4). However, these substances may cause undesirable side effects such as dryness of the mouth, cardiovascular disorder, visceral ischemia and intestinal disturbance, and clinical apply must be impractical. On the other hand, terbutaline sulfate, which is a  $\beta$ -stimulatin agent, has fewer cardiac disorders. Then it is clinically usable for the purpose of inhibiting exocrine pancreatic secretion (2,5).

In 1987, Joehl and his associates reported that terbutaline inhibited both pancreatic biocarbonate and enzyme secretion (5). They also demonstrated that terbutaline inhibited secretin-stimulated secretion of the pancreatic juice and its biocarbonate in healthy volunteers, and it reduced daily volume of a discharge in a patient with external pancreatic fistula without cardiac disorder. From these facts, terbutaline sulfate is clinically useful to inhibit the exocrine pancreatic secretion. In the present four patients, complete healing of anastomotic leakage could be obtained by administration of terbutaline sulfate. Especially, in case 1, it was clearly demonstrated that volume of the duodenal juice and activity of pancreatic enzyme gradually decreased in response to administration of terbutaline sulfate.

The mechanism by which the exocrine pancreatic secretion is inhibited after terbutaline administration has not been clearly shown. It is speculated that its inhibitory effects do not depend on the activity of endogenous gut hormones and pancreatic blood flow (2,5-7), but it acts on the nerve of the acinar cells of the pancreas (2,5). In other words, these observations support evidence that  $\beta$ -adrenergic stimulators act in the splanchnic nervous system of the acinar cells, resulting inhibition of the exocrine pancreatic secretion.

In conclusion, terbutaline sulfate is useful for anastomotic leakage after gastric operation, but its administration must be further evaluated in a larger group of patients.

## REFERENCES

- 1) Weiner, N. (1980) Atropine, scopolamine, and related antimuscarinic drugs. In: The Pharmacological Basis of Therapeutics, (Gilman, A.G., Goodman, L.S., Gilman, A.) pp.120 - 137, MacMillan, New York
- 2) Joehl, R.J., Nahrwold, D.L. (1985) Inhibition of human pancreatic secretion by terbutaline as a potential agent for treating patients with pancreatic fistula. Surg. Gynecol. Obstet., 160, 109 - 114
- 3) Barolow, T.E., Greenwell, J.R., Harper, A.A., Scratcherd, T. (1974) The influence of the splanchnic nerves on the external secretion, blood flow, and conductance of the rat pancreas. J. Physiol., 236, 421 - 433
- 4) Rudick, J., Gonda, M., Rosenberg, R., Chapman, M., Dreiling, D.A., Janowitz, H.D. (1973) Effect of a beta-adrenergic receptor stimulant (isoproterenol) on pancreatic exocrine secretion. Surgery., 74, 338 - 343
- 5) Joehl, R.J., Kelly, G.A., Nahrwold, D.L. (1981) Terbutaline inhibits pancreatic secretion. J. Surg. Res., 30, 236 - 240
- 6) Joehl, R.J., Kelly, G.A., Nahrwold, D.L. (1980) Inhibition of cholecystinin-stimulated pancreatic secretion. Surg. Forum., 31, 198 - 203
- 7) Swan, K.G., Reynolds, D.G. (1971) Adrenergic mechanism in canine mesenteric circulation. Am. J. Physiol., 220, 1779 - 1781