

Is Nucleus Accumbens-Associated Protein 1 A Feasible Marker for Distinguishing Oral Malignancies from Non-malignancies? First Investigation of Nucleus Accumbens-Associated Protein 1 Expression in Oral Lesions

Koichiro OHIRA¹⁾, Katsumi HIDESHIMA¹⁾, Takeshi URANO²⁾ and Joji SEKINE¹⁾

¹⁾Department of Oral and Maxillofacial Surgery, Shimane University Faculty of Medicine, 89-1 Enya-cho, Izumo, Shimane 693-8501, Japan

²⁾Department of Biochemistry, Shimane University Faculty of Medicine, 89-1 Enya-cho, Izumo, Shimane 693-8501, Japan

(Received November 29, 2014; Accepted December 8, 2014)

This study was planned to investigate the feasibility of nucleus accumbens-associated protein 1 (NAC1) for distinguishing oral malignancies from non-malignancies. Subjects comprised 165 patients including 32 with lichen planus, 19 with hyperkeratosis, 67 with epithelial dysplasia, 10 with carcinoma in situ, and 37 with oral squamous cell carcinoma (OSCC). Normal oral mucosa (NOE) was taken from 15 healthy participants. NAC1 labeling indices (LIs) and NAC1 immunoreactivity intensity were examined. In OSCC, the correlation between clinical behavior and NAC1 expression was also examined. NAC1 expression was stronger in NOE and OSCC, but weaker in other lesions. NAC1 LIs correlated strongly with NAC1 immunoreactivity intensity. No correlation was observed between NAC1 LIs/NAC1 immunoreactivity intensity and tumor behavior such as lymph node involvement in OSCC. Though there were differences in NAC1 expression in various oral lesions, NAC1 is not a definitive marker for distinguishing oral malignancies from non-malignancies.

Key words: oral mucosa, lichen planus, hyperkeratosis, epithelial dysplasia, oral squamous cell carcinoma, nucleus accumbens-associated protein 1 (NAC1)

Corresponding author: Joji Sekine, D.D.S., Ph.D.

Department of Oral and Maxillofacial Surgery, Shimane University Faculty of Medicine, 89-1 Enya-cho, Izumo, Shimane 693-8501, Japan

Tel: +81-853-20-2301

Fax: +81-853-20-2299

E-mail: georges@med.shimane-u.ac.jp

INTRODUCTION

The differential diagnosis for oral lesions includes a number of non-neoplastic conditions. When considering the differential diagnosis for oral lesions, the squamous epithelium should be considered because most oral neoplasms originate in this tissue [1]. Lesions such as lichen planus, frictional keratosis, and tobacco pouch keratosis must be ruled out before a clinical diagnosis of leukoplakia can be made. As with most white oral lesions, the color results from a thickened keratin layer or thickened spinous layer, which mask the normal vascularity (redness) of the underlying connective tissue [2]. Although leukoplakia is considered a premalignant lesion [3], use of this clinical term in no way suggests that the histopathologic features of epithelial dysplasia are present in all lesions. In fact, dysplastic epithelium or frankly invasive carcinoma is found in only 5-25% of leukoplakia biopsy specimens [4]. The precancerous nature of leukoplakia has been established, but not so much on the basis of this association or the fact that more than one-third of squamous cell carcinomas are associated with leukoplakia in close proximity. Therefore, leukoplakia is by far the most common oral precancer, representing 85% of such lesions [4].

Microscopically, the pathology of lichen planus is typically characterized by hyperkeratosis with a variably thickened spinous layer (acanthosis), and degenerated basal cells, and squamous cells abut the lamina propria containing a variably intense lymphohistiocytic infiltrate [5, 6]. In addition, oral lichen planus is

associated with a 0.4-0.6% rate of malignant transformation to oral squamous cell carcinoma [7, 8].

Neoplasia can be defined as all focal proliferative lesions, benign tumors, primary cancers, and metastases with the potential to affect a given cell system [4]. Precursor states to invasive cancer are proliferative lesions with atypical cells confined to a single tissue component with a limited growth span and only rare progression to cancer. Focal abnormal cell proliferation results in areas of increased cell numbers or areas of hyperplasia, whereas tissue hypertrophy is growth that increases cell mass within a tissue compartment. Hyperplasia may or may not involve atypia, which denotes individual cells with abnormal nuclear architecture.

Epithelial dysplasia, on the other hand, refers to anomalous tissue organization. Dysplastic lesions are typically confined to a single tissue compartment and may progress to cancer, but do not always do so. Regarding the severity of epithelial dysplasia, mild epithelial dysplasia refers to alterations limited principally to the basal and parabasal layers, whereas moderate epithelial dysplasia shows involvement from the basal to mid-portion of the spinous layer, and severe epithelial dysplasia shows alteration from the basal layer to a level above the midpoint of the epithelium [2]. When the entire thickness of the epithelium is involved, the term carcinoma in situ is used. Carcinoma in situ is defined as dysplastic epithelial cells extending from the basal layer to the mucosal surface and showing an aspect of malignancy [2]. Carcinoma in situ and intraepithelial neoplasia involve lesions with morphologic characteristics of cancer, including atypical cells and dysplastic organization, but by definition are confined to one tissue compartment with no penetration to adjacent tissue compartments. In other words, they do not show invasion through the basement membrane [2, 4]. However, accurate diagnosis of such white lesions is difficult in the clinical field [3], and even with histopathologic specimens, precise diagnosis of dysplasia from intraepithelial lesions is difficult [2].

Nucleus accumbens-associated protein 1 (NAC1) is a member of the Pox virus and Zinc finger/Bric-a-brac Tramtrack Broad complex family of proteins that mediates several cellular functions including proliferation, apoptosis, transcription control, and

cell morphology maintenance [9, 10]. Furthermore, NAC1 is reported to be significantly overexpressed in several types of human carcinoma [11]. The level of NAC1 expression correlates with tumor recurrence in ovarian serous carcinomas, and intense NAC1 immunohistochemistry in primary ovarian tumors is an indicator of early recurrence [9, 11-15]. However, no NAC1 expression has been reported in normal oral epithelium (NOE) or in oral lesions such as premalignancies and malignancies.

This preliminary investigation is the first to study NAC1 expression in oral lesions. We evaluated the associations between NAC1 expression in NOE and various lesions including lichen planus, hyperkeratosis, carcinoma in situ, and oral squamous cell carcinoma to verify whether NAC1 is a feasible marker for distinguishing oral malignancies from non-malignancies.

PATIENTS AND METHODS

Participants

Subjects comprised 165 patients (88 men, 77 women; mean age, 65.2 years; age range, 21-91 years), including 32 with lichen planus (12 men, 20 women; mean age, 59.1 years; age range, 21-80 years; tongue, 2 cases; gingiva, 7 cases; buccal mucosa, 18 cases; palate, 2 cases; lip, 2 cases), 19 with hyperkeratosis (12 men, 7 women; mean age, 62.4 years; age range, 41-91 years; tongue, 7 cases; gingiva, 10 cases; palate, 2 cases), 67 with epithelial dysplasia (29 men, 38 women; mean age, 68.4 years; age range, 39-91; tongue, 37 cases; gingiva, 18 cases; buccal mucosa, 8 cases; palate, 2 cases; lip, 2 cases), 10 with carcinoma in situ (6 men, 4 women; mean age, 68.4 years; age range, 39-91 years; tongue, 8 cases; gingiva, 2 cases), and 37 with oral squamous cell carcinoma (29 men, 8 women; mean age, 65.8 years; age range, 34-84 years; tongue, 17 cases; gingiva, 16 cases; buccal mucosa, 3 cases; oral floor, 1 case) (Table 1). All diagnoses were made at the Department of Oral and Maxillofacial Surgery, Shimane University Hospital, Japan from 1980 to January 2013. Detailed information on the oral squamous cell carcinoma cases including primary sites and cervical lymph node involvement according to the TNM Atlas [16] is shown in Table 2.

NOE was taken from 15 healthy participants (7 men, 8 women; mean age, 61.9 years; age range, 49-77 years) with no symptoms or medical history of any oral mucous disorder who provided consent for their samples to be used as standard controls (Table 1). All participants provided informed consent to participate following approval of the study protocol (March 26, 2012) by the Ethics Committee of Shimane University Hospital, Japan.

Tissue samples and NAC1 immunohistochemistry

All patients underwent preoperative biopsy at the Department of Oral and Maxillofacial Surgery, Shimane University Hospital. Biopsy specimens taken from the margin of the lesion were fixed with 10% neutral buffered formalin for 24 h, processed as routine paraffin-embedded sections, stained with

hematoxylin and eosin, and analyzed by pathology specialists of the Department of Pathology, Shimane University Hospital who made a histopathological diagnosis. Fifteen samples of NOE taken from normal gingiva were also processed as paraffin-embedded sections.

After deparaffinization and rehydration, sections were incubated for 30 min in 0.3% hydrogen peroxide in methanol to quench endogenous peroxidase activity. Pretreatment consisted of autoclave antigen retrieval in tablets of phosphate buffered salts (pH 7.4, TAKARA BIO Inc., Shiga, Japan). Ten tablets of phosphate buffered salts were dissolved in distilled water to make a total volume of 1,000 ml (9.57 mM, pH 7.35-7.65). Sections for all immunohistochemistry were sequentially incubated with diluted 10% rabbit blocking serum to block nonspe-

Table 1. Nucleus accumbens-associated protein 1 (NAC1) labeling indices and NAC1 expression intensity in each type of lesion

		NAC1 labeling index (mean ± SD)	NAC1 immunoreactivity intensity (mean ± SD)
Normal oral epithelium	15	58.8 ± 14.3	119.6 ± 10.7
Lichen planus	32	38.6 ± 9.4	124.1 ± 9.7
Hyperkeratosis	19	32.6 ± 14.3	138.8 ± 4.9
Epithelial Dysplasia			
Mild	34	37.8 ± 14.6*	134.8 ± 7.1**
Moderate	20	24.7 ± 15.0*	128.2 ± 10.9**
Severe	13	26.7 ± 16.6*	133.4 ± 9.1**
Total		31.7 ± 16.1	132.5 ± 9.1
Carcinoma in situ	10	58.1 ± 15.2	120.8 ± 6.8
Oral squamous cell carcinoma			
Well	23	57.3 ± 12.1	118.2 ± 7.0
Moderate	12	58.0 ± 14.1	120.4 ± 8.2
Poor	2	61.2 ± 8.3	123.7 ± 4.4
Total		57.7 ± 12.3	119.2 ± 7.3

Significant differences among mild, moderate, and severe dysplasia evaluated by nucleus accumbens-associated protein 1 (NAC1) labeling indices* / NAC1 immunoreactivity intensity** (p<0.001, ANOVA).

cific reactions and treated with primary antibody.

After treating sections with streptavidin biotin reagent in a HISTOFINE SAB-PO (M) KIT (Nichirei, Tokyo, Japan) using NAC1 mouse monoclonal antibody (diluted 1:1,000 overnight at 4°C) [17], they were incubated in a substrate solution consisting of

0.05% diaminobenzidine tetrahydrochloride. Counterstaining was done with Mayer's hematoxylin for 30 s. Negative controls for immunohistochemistry were incubated with phosphate buffered saline instead of the primary antibodies and showed no positive reaction.

Table 2. Cervical lymph node involvement in oral squamous cell carcinoma

	n	NAC1 immunoreactivity	
		NAC1 labeling index (mean ± SD)	intensity (mean ± SD)
Tumor site			
Tongue	17	56.5 ± 13.6	117.4 ± 6.6
Gingiva	16	57.6 ± 11.6	121.6 ± 8.2
Buccal mucosa	3	62.8 ± 14.3	117.5 ± 5.4
Mouth floor	1	64.3	116.1
pN			
0	17	58.6 ± 14.2	117.8 ± 9.0
1	8	57.5 ± 9.6	119.8 ± 5.4
2b	12	56.6 ± 12.3	120.8 ± 5.8
		57.0 ± 11.0	120.4 ± 5.5
No of pN			
0	17	58.6 ± 14.2	117.8 ± 9.0
1	9	58.2 ± 9.2	119.9 ± 5.0
2	4	53.9 ± 15.9	122.6 ± 7.8
3	4	54.5 ± 14.9	118.6 ± 5.2
4	3	60.5 ± 6.2	121.4 ± 6.0
Level			
pN0	17	58.6 ± 14.2	117.8 ± 9.0
II	13	58.2 ± 11.5	120.9 ± 6.0
III	3	58.8 ± 7.5	116.7 ± 0.6
II+III	2	52.9 ± 1.3	121.7 ± 9.0
II+IV	2	50.1 ± 22.7	121.8 ± 3.1

No significant differences were seen in the NAC1 LIs and immunoreactivity intensity between the tongue, gingiva, buccal mucosa, and oral floor. No significant correlations were seen between the NAC1 LIs or NAC1 immunoreactivity intensity and pathologic N stage, number of metastatic lymph nodes, or level of metastases of cervical lymph node involvement.

NAC1 labeling indices

All sections were examined by the first author under a standard light microscope ($\times 40$ objective lens), and images were captured with an attached digital camera to estimate the number of NAC1-positive cells. The structure of the basal cell layers was preserved in cases of NOE, lichen planus, hyperkeratosis, epithelial dysplasia, and carcinoma in situ, and the cells from the basal to the keratinized layers in the field of view constituted the bottom-most 20 basal cells, which were counted in at least 10 sites per case to obtain the average NAC1 LI (labelled cells / total cells counted $\times 100\%$) (Fig. 1A). In cases of oral squamous cell carcinoma, at least 100 cells including NAC1-positive and -negative cells were counted at the invasive front of the lesion (Fig. 1B). Because they didn't show the clear basal cell layers.

NAC1 immunoreactivity intensity

The nuclear margins of NAC1-positive cells (at least 100 cells) were correctly delineated under high-magnification view ($\times 40$ objective lens) using a standard light microscope to ensure the quality of the measurement. NAC1 immunoreactivity intensity was then evaluated in Image J v1.47 (National Institute of Health, Bethesda, MD) by analyzing the brightness of each pixel in RGB images (Fig. 1C), with high values indicating weak intensity and low values indicating strong intensity.

Correlation between NAC1 labeling indices / NAC1 immunoreactivity and cervical lymph node metastases in oral squamous cell carcinoma

Thirty-seven patients with oral squamous cell carcinoma had undergone tumorectomy as well as supraomohyoid or radical neck dissection. All dissected lymph nodes were examined to determine the pathologic N classification (pN) and the number of involved metastatic lymph nodes. Cervical lymph node level was determined based on the cervical lymph node metastatic guide [16].

STATISTICAL ANALYSIS

The results were analyzed using R. app GUI 1.64 for Mac OS (R Foundation for Statistical Computing, Vienna, Austria). NAC1 LIs and the immunore-

activity intensity were compared among NOE, lichen planus, hyperkeratosis, epithelial dysplasia and oral squamous cell carcinoma using the Kruskal-Wallis test or ANOVA.

Regarding the clinical features of oral squamous cell carcinoma, significant differences between primary sites as well as lymph node metastases (pN, number of metastatic lymph nodes and level of involvement) and NAC1 LIs / NAC1 immunoreactivity intensity were determined using the ANOVA for continuous variables. A p value < 0.01 was considered significant. Statistical analysis using ANOVA or Kruskal-Wallis test was indicated following Bartlett's test.

RESULTS***NAC1 expression***

In NOE and carcinoma in situ, NAC1-positive cells were strongly expressed in the basal cell layers, and uniformly distributed in all epithelial layers. In epithelial dysplasia, hyperkeratosis and lichen planus, NAC1-positive cells were distributed mainly from the basal cell to spinous layers, and were also found in the proliferating area of oral squamous cell carcinoma (Fig. 2).

NAC1 labeling indices

Figure 3A shows the significant differences among NOE, lichen planus, hyperkeratosis, epithelial dysplasia and oral squamous cell carcinoma in NAC1 LIs ($p < 0.001$, Kruskal-Wallis test). Detailed information of NAC1 LIs are shown in Table 1. Significant differences were observed among upon detailed grading of oral ED by WHO classification and the differentiation of OSCC, and other lesions including NOE in NAC1 LIs ($p < 0.001$, ANOVA, Fig. 3B).

As shown in Table 1, significant differences were seen in NAC1 LIs among mild, moderate, and severe dysplasia ($p < 0.001$, ANOVA). However, no significant differences were seen between each histological type of NAC1 LIs from the viewpoint of squamous cell carcinoma differentiation ($p = 0.91$, ANOVA).

NAC1 immunoreactivity intensity

The pixel count was 119.6 ± 10.7 for NOE, 119.2 ± 7.3 for oral squamous cell carcinoma, 132.5

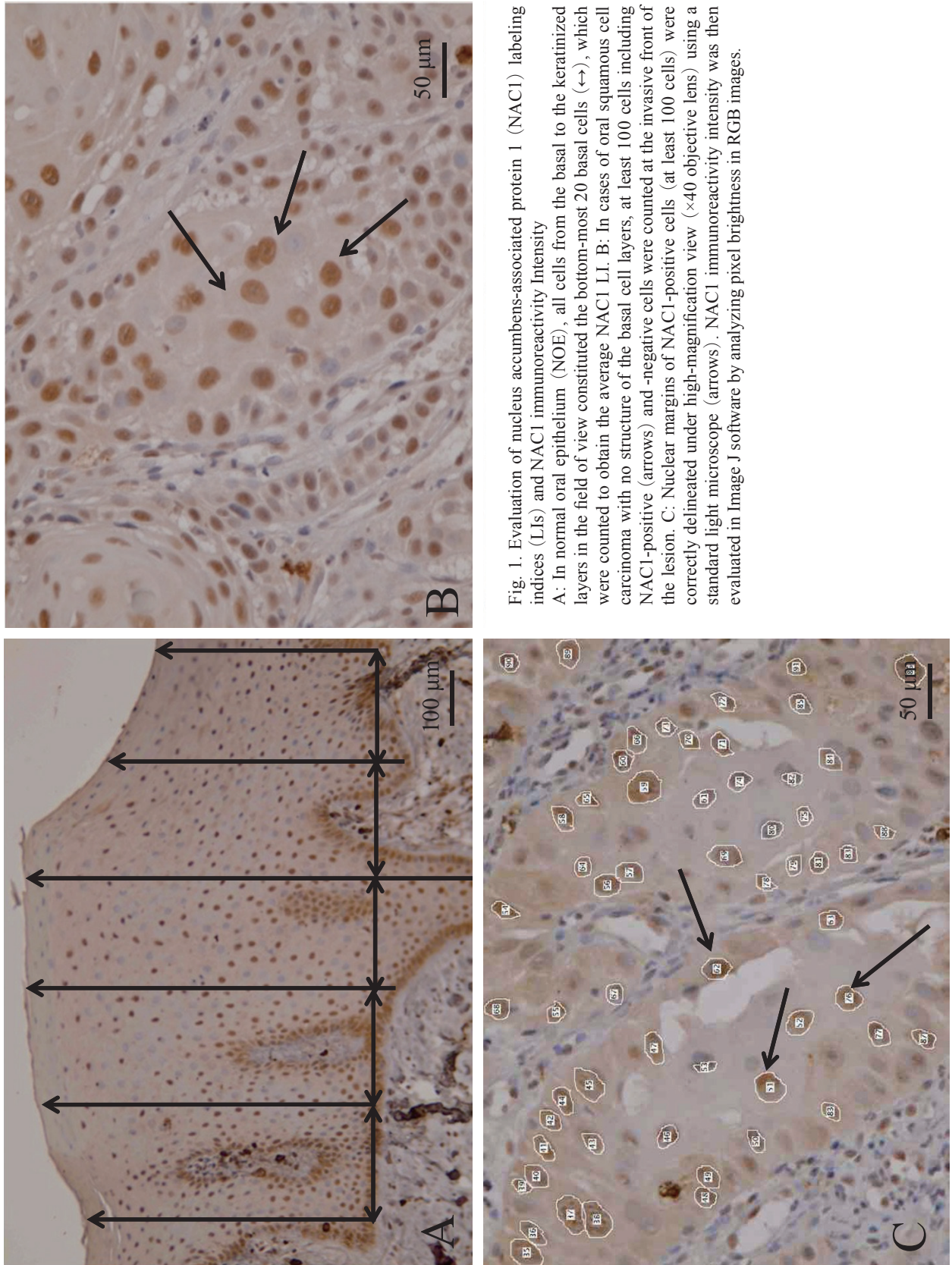


Fig. 1. Evaluation of nucleus accumbens-associated protein 1 (NAC1) labeling indices (LIs) and NAC1 immunoreactivity intensity
 A: In normal oral epithelium (NOE), all cells from the basal to the keratinized layers in the field of view constituted the bottom-most 20 basal cells (\leftrightarrow), which were counted to obtain the average NAC1 LI. B: In cases of oral squamous cell carcinoma with no structure of the basal cell layers, at least 100 cells including NAC1-positive (arrows) and -negative cells were counted at the invasive front of the lesion. C: Nuclear margins of NAC1-positive cells (at least 100 cells) were correctly delineated under high-magnification view ($\times 40$ objective lens) using a standard light microscope (arrows). NAC1 immunoreactivity intensity was then evaluated in Image J software by analyzing pixel brightness in RGB images.

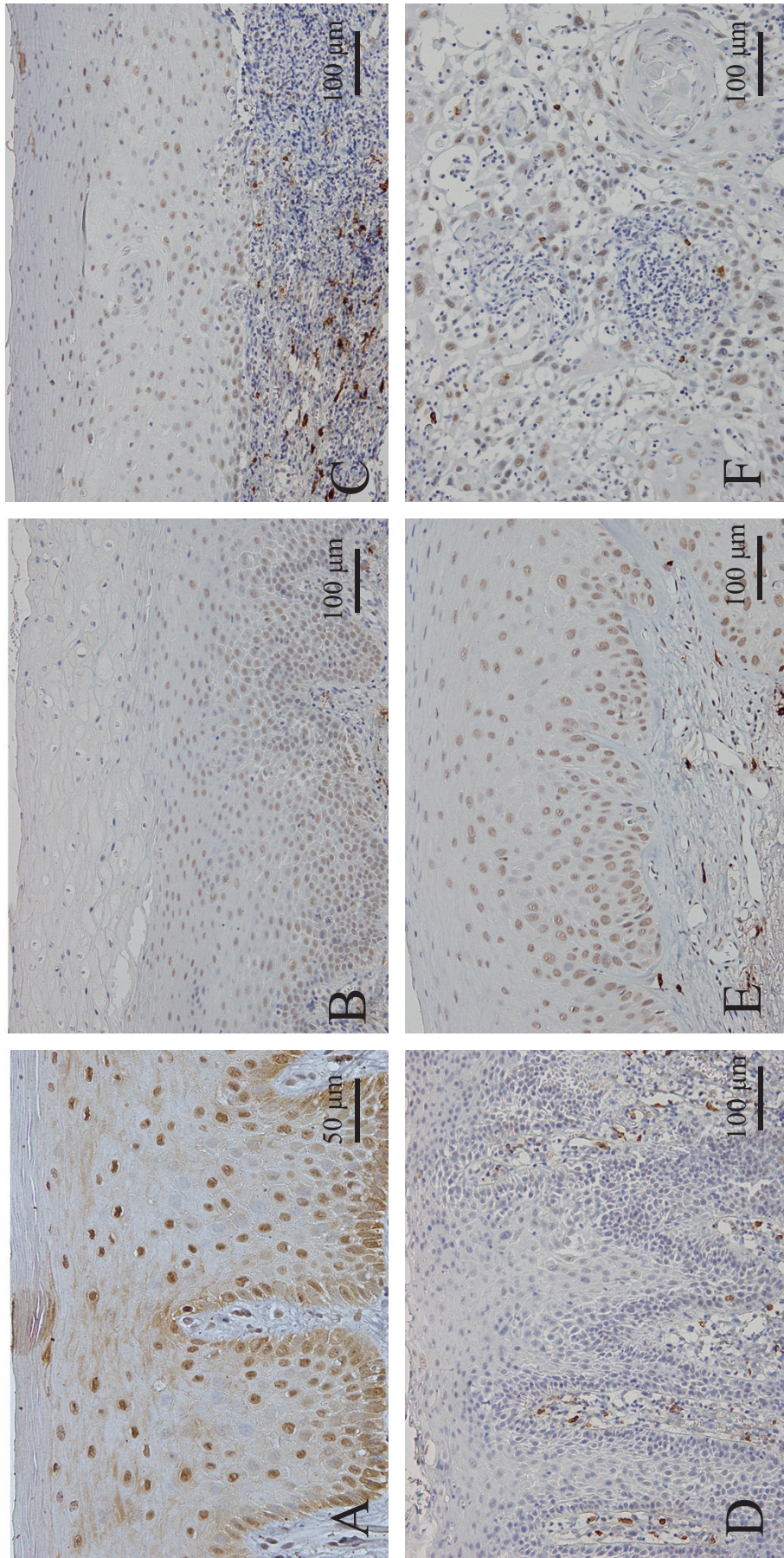


Fig. 2. NAC1 expression

In NOE and carcinoma in situ, NAC1-positive cells were strongly expressed in the basal cell layers and uniformly distributed in all epithelial layers. In hyperkeratosis, lichen planus, and epithelial dysplasia, NAC1-positive cells were distributed mainly from the basal cell to spinous layers, and were also found in the proliferating areas of carcinoma in situ and oral squamous cell carcinoma. A: Normal oral epithelium ($\times 40$). B: Hyperkeratosis ($\times 20$). C: Lichen planus ($\times 20$). D: Epithelial dysplasia ($\times 20$). E: carcinoma in situ ($\times 20$). F: oral squamous cell carcinoma ($\times 20$).

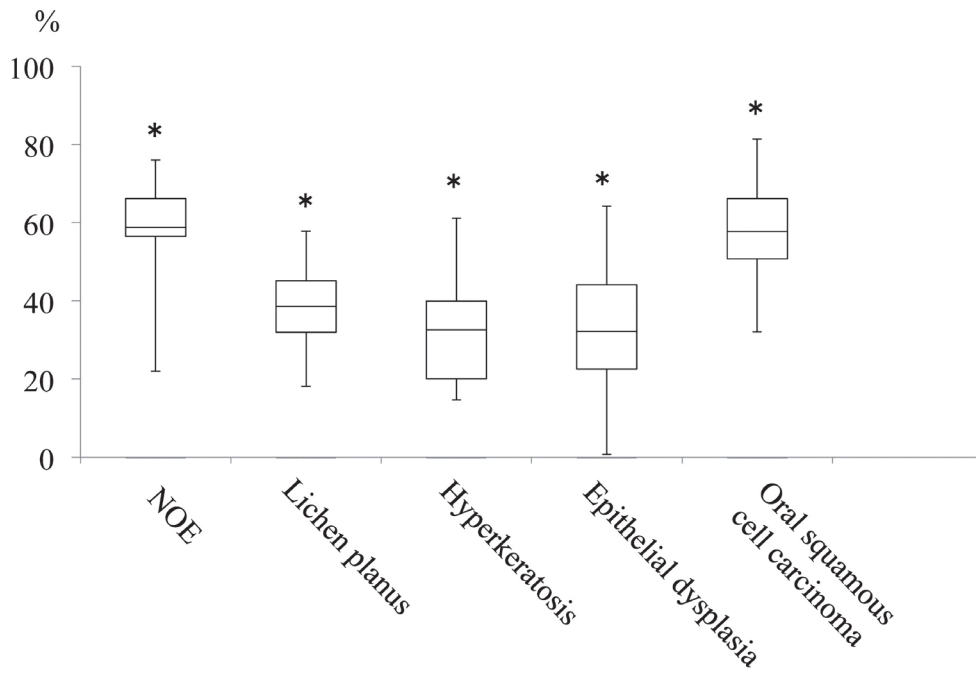


Fig. 3A. Summary of NAC1 LIs in various oral lesions
 There were significant differences among NOE, lichen planus, hyperkeratosis, and oral squamous cell carcinoma in NAC1 LIs ($p < 0.001$, Kruskal-Wallis test). The mean of Epithelia dysplasia showed the lowest LIs (see Table 1). NOE: normal oral epithelium

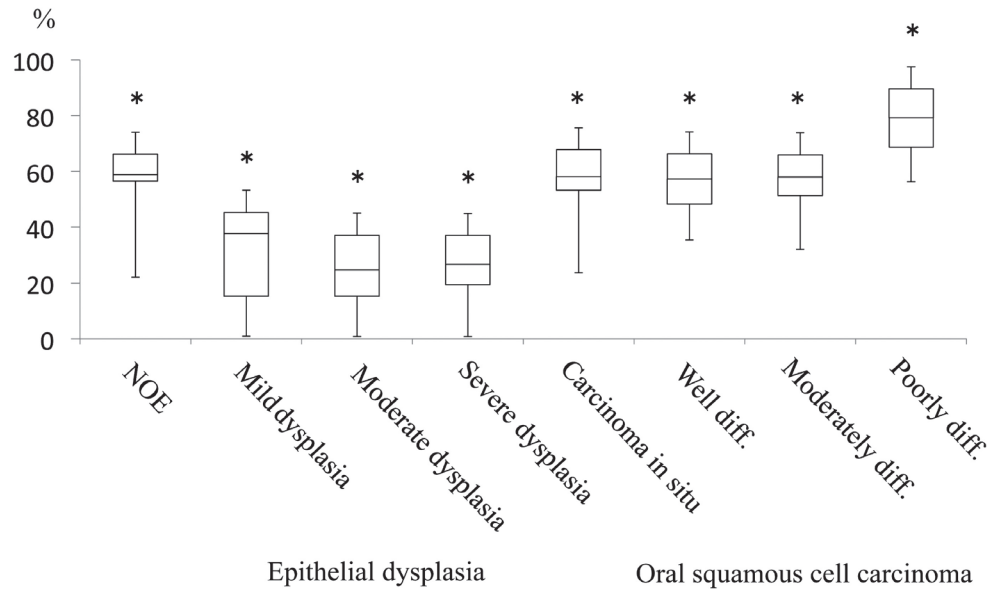


Fig. 3B. Comparison of NAC1 LIs in normal oral mucosa, epithelial dysplasia, carcinoma in situ, and oral squamous cell carcinoma by histological severity and tumor differentiation
 There were significant differences among mild, moderate and severe dysplasia in NAC1 LIs. NAC1 LIs of carcinoma in situ and well-, moderately, and poorly differentiated oral squamous cell carcinoma were higher than those of dysplasia cases, with poorly differentiated oral squamous cell carcinoma showing the highest LIs ($p < 0.001$, ANOVA). NOE: normal oral epithelium, Well diff.: well differentiated, Moderate diff.: moderately differentiated, Poorly diff.: poorly differentiated

± 9.1 for epithelial dysplasia, 124.1 ± 9.7 for lichen planus, and 138.8 ± 4.9 for hyperkeratosis (Fig. 4A, Table 1). Significant differences were seen among each type of lesion, including NOE in NAC1 immunoreactivity intensity ($p < 0.001$, Kruskal-Wallis test, Fig. 4B).

As shown in Table 1, significant differences were seen in the pixel count for mild, moderate, and severe dysplasia ($p < 0.001$, ANOVA). However, regarding the pixel count from the viewpoint of squamous cell carcinoma differentiation, no significant differences were seen between each of them ($p = 0.48$, ANOVA).

Correlation between NAC1 LIs / NAC1 immunoreactivity intensity and primary sites of oral squamous cell carcinoma

No significant differences were seen in NAC1 LIs ($p = 0.73$, ANOVA) and immunoreactivity intensity ($p = 0.24$, ANOVA) between the tongue, gingiva, buccal mucosa, and oral floor.

Correlation between NAC1 LIs / NAC1 immunoreactivity intensity and cervical lymph node involvement in oral squamous cell carcinoma

The correlations between NAC1 LIs / NAC1 immunoreactivity intensity and pathologic N stage are shown in Table 2. No significant correlations were seen between NAC1 LIs and NAC1 immunoreactivity intensity and pathologic N stage (LI, 0.91; intensity, 0.53; ANOVA), number of metastatic lymph nodes (LI, 0.93; intensity, 0.78; ANOVA) or in the level of metastases with cervical lymph node involvement (LI, 0.71; intensity, 0.79; ANOVA).

DISCUSSION

In this study, expression of NAC1 in various oral lesions was evaluated by measuring NAC1 LIs and NAC1 immunoreactivity intensity, which revealed some striking features. NAC1 LIs were almost the same in NOE and oral squamous cell carcinoma, but lower in epithelial dysplasia. NAC1 immunoreactivity intensity was lower in NOE and oral squamous cell carcinoma than in epithelial dysplasia. On the other hand, lichen planus and hyperkeratosis showed lower NAC1 LIs compared with NOE and oral squamous cell carcinoma, but higher NAC1 LIs

than in epithelial dysplasia. However, as intensity was analyzed on RGB images, the lower NAC1 immunoreactivity intensity inversely indicated high expression of NAC1. Namely, this study revealed that NAC1 LIs correlated closely with NAC1 immunoreactivity intensity in NOE and various oral lesions and that NAC1 expression in NOE and oral squamous cell carcinoma was notably higher than in lichen planus, hyperkeratosis, and epithelial dysplasia, both quantitatively and qualitatively. To our knowledge, this is the first investigation on NAC1 expression in oral lesions.

Our results revealed that NAC1 expression in NOE was as high as that in malignant tissue. NAC1 expression, however, is reported to be undetectable or very weak in normal ovarian surface epithelium [11], while no expression of NAC1 protein has been noted in normal cervical tissue or cervical intraepithelial neoplasia [14]. On the other hand, NAC1 is overexpressed in the normal endometrium during the early and mid-proliferative phases as it is essential for growth and survival in the normal endometrium [18]. As NAC1 is considered to have oncogenic potential [13], NAC1 expression is upregulated by estradiol and involved in estradiol-induced cell growth in endometrial cells from the viewpoint of estrogen-induced endometrium carcinogenesis [18].

Regarding NOE, the epithelium of the gingiva, oral floor, buccal mucosa, and palate derives from the embryonic ectoderm, whereas that of the tongue is derived from both the endoderm and ectoderm [19]. Histologically, the oral mucosa is stratified, but consists of basal, spinous, intermediate, and superficial cell layers, and epithelial undulations, known as rete pegs, can be seen protruding downwards into the lamina propria [20]. Cell division in all oral epithelial cells takes place solely in the basal cell layer. After dividing, the committed cells, similar to epidermal keratinocytes, undergo a differentiation process leading to expression of structural keratin proteins and loss of intracellular organelles as cells move superficially, begin to flatten, and are eventually sloughed off the surface [19, 21-23].

NAC1 has recently been identified as an important transcriptional regulator as part of an extended regulatory network necessary for preserving the pluripotent state of embryonic stem cells [24, 25]. NAC1

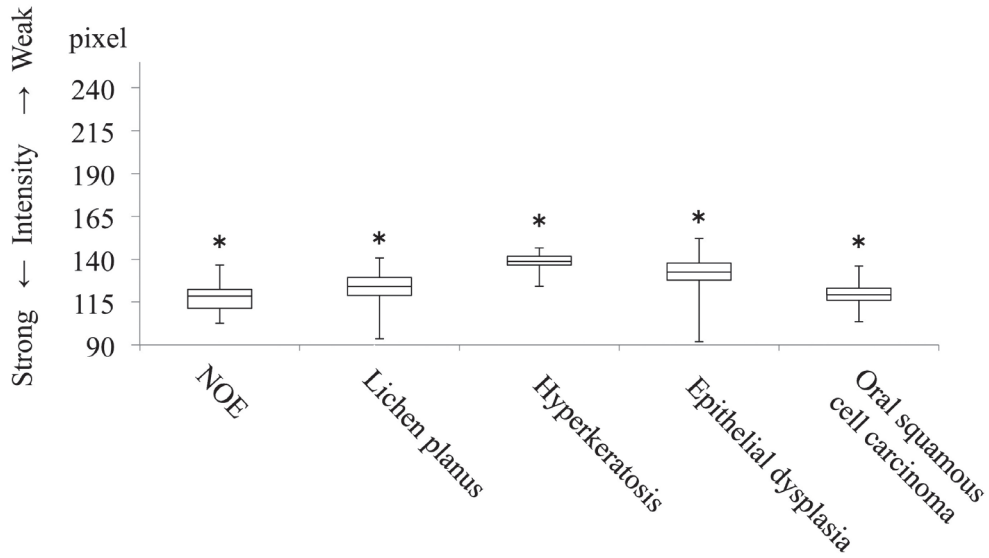


Fig. 4A. Summary of NAC1 immunoreactivity intensity in various oral lesions
 NAC1 immunoreactivity intensity was strongest for hyperkeratosis ($p < 0.001$, Kruskal-Wallis test).
 NOE: normal oral epithelium

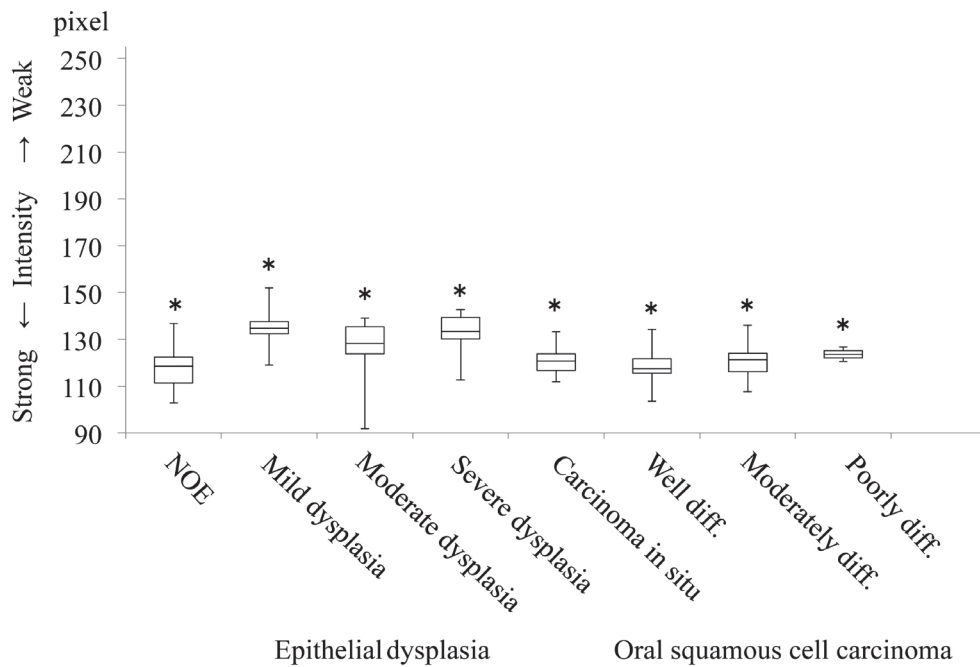


Fig. 4B. Comparison of NAC1 immunoreactivity intensity of normal oral mucosa, epithelial dysplasia, carcinoma in situ, and oral squamous cell carcinoma by histological severity and tumor differentiation
 Severe dysplasia showed the strongest intensity. Significant differences were seen between NAC1 immunoreactivity intensity and each histological type, including NOE ($p < 0.001$, ANOVA). NOE: normal oral epithelium, Well diff.: well differentiated, Moderate diff.: moderately differentiated, Poorly diff.: poorly differentiated

is a primary Nanog-interacting protein that is part of the protein regulatory complex responsible for maintaining pluripotency [25]. NAC1 has been shown to regulate transcription of the transcription factors, Nanog, Oct4, and Sox2, which are essential for the development and maintenance of the pluripotent state of embryonic stem cells [24]. Though little work has been done to identify oral epithelial stem cells compared with other tissue systems [20], a Sox2-Cre-ER; Rosa26-LSL-EYFP mouse model showed that Sox2 is expressed by basal layer stem cells for at least 10 months after labeling in the dorsum of the tongue [26]. Cre-ER mouse constructs are currently available for several genes shown to mark stem cell populations in other epithelial tissues [20]. When considering the strong expression of NAC1 in NOE, Sox2 was thought to play an important role in downregulating the epithelial cells derived from the ectoderm, while NAC1 likely participated in transcriptional regulation of Sox2 in the maintenance of cell pluripotency.

In our study, NAC1 expression was also stronger in malignant tissues including carcinoma in situ, which can be expected since oral squamous cell carcinoma has a high potential for both invasion and cervical lymph nodes metastasis [27]. This finding is reasonable, as NAC1 was reported to be overexpressed in cervical squamous cell carcinoma with gene amplification [14, 15], and NAC1 expression was also more common in cervical adenocarcinomas/adenosquamous carcinomas, as well as in serous ovarian carcinoma, which are the most aggressive types of carcinoma [13, 15]. Overexpression of NAC1 is seen in several types of human carcinomas arising from not only the ovary, cervix, and endometrium, but also the breast and colon [11, 14, 17, 28].

Generally, dysplastic changes in the oral intraepithelial cells are associated with transformation from normal to malignant tissue [29]. The more dysplastic the epithelium becomes, the more the atypical epithelial changes extend to involve the entire thickness of the epithelium. van Zyl *et al* [30] showed that aneuploidy peaks in cases of mild dysplasia were predominantly in a peri-diploid position while the mean DNA index values gradually increased in line with the severity of oral epithelial dysplasia. The histopathologic alterations of dysplastic epithe-

lial cells are very similar to those of oral squamous cell carcinoma [2]. Our results showed weaker NAC1 expression in epithelial dysplasia than in oral squamous cell carcinoma, which is reasonable, as NAC1 is a driver gene with significant cell growth and survival effects in ovarian carcinomas [10].

First, we hypothesized that NAC1 expression in malignancies is stronger than in non-malignancies. However, our results showed very weak expression in epithelial dysplasia compared with NOE. Dost *et al* [31] concluded that the severity of oral epithelial dysplasia is not associated with a risk of malignant transformation. Although no studies have assessed the correlation between grading of epithelial dysplasia and NAC1 expression in other fields, and as there are few detailed studies on the mechanism of cell differentiation in oral epithelium [32, 33], our results suggest that oral epithelial dysplasia is an independent lesion from malignancies. More investigation is necessary to reveal the mechanism of weak NAC1 expression in epithelial dysplasia.

NAC1 is known to play important roles in the proliferation and growth of tumor cells and in chemotherapy in the field of gynecology [34, 35]. Furthermore, NAC1 expression is a prognostic factor for patients with cervical squamous cell carcinoma treated by conventional radiotherapy [14, 15]. Some clinical investigations have reported the relationship between overexpression of NAC1 and the clinical behavior of malignancies and patient prognosis [9, 11-13]. Ovarian carcinomas overexpressing NAC1 are more dependent on activation of cell proliferation and survival than those without such overexpression [13]. However, in pancreatic ductal adenocarcinoma, poor prognosis is associated with low expression of NAC1 [36]. In the present study, we found no significant associations between NAC1 expression and cervical lymph node involvement in oral squamous cell carcinoma. The difference between NAC1 expression and clinical behavior in various carcinomas would be speculated to depend on the difference in carcinogenesis. Further study would be needed to elucidate the relationship between NAC1 expression and the clinical behavior of oral squamous cell carcinoma.

In summary, though there were differences in NAC1 expression in various oral lesions, NAC1 is

not a definitive marker for distinguishing oral malignancies from non-malignancies.

ACKNOWLEDGMENTS

The authors are grateful to Dr. Kentaro Nakayama, Department of Obstetrics and Gynecology, Shimane University Faculty of Medicine for providing expert technical advice regarding NAC1 immunohistochemistry.

Conflicts of Interest: None

REFERENCES

- 1) Fu YS, Wenig BM, Abemayor E and Wenig BL (2001) Head and neck pathology with clinical correlations, pp3-37, Churchill Livingstone, Philadelphia.
- 2) Nevill BW, Damm DD, Allen CM and Bouquot JE (2001) Oral & Maxillofacial Pathology, 2nd ed. pp315-387, W.B. Saunders, Philadelphia.
- 3) Cawson RA, Binnie WH, Barrett AW and Wright JM (2001) Chronic white lesions and premalignant lesions. Oral Disease, 3rd ed. pp14.1-14.24, Mosby, London.
- 4) Fu YS, Wenig BM, Abemayor E and Wenig BL (2001) Head and neck pathology with clinical correlations, pp456-483, Churchill Livingstone, Philadelphia.
- 5) Jungell P (1991) Oral lichen planus. A review. *Int J Oral Maxillofac Surg* 20: 129-315.
- 6) Scully C and el-Kom M (1985) Lichen planus: review and update on pathogenesis. *J Oral Pathol* 14: 431-458.
- 7) Barnard NA, Scully C, Eveson JW, Cunningham S and Porter SR (1993) Oral cancer development in patients with oral lichen planus. *J Oral Pathol Med* 22: 421-424.
- 8) Holmstrup P, Thorn JJ, Rindum J and Pindborg JJ (1988) Malignant development of lichen planus-affected oral mucosa. *J Oral Pathol* 17: 219-225.
- 9) Rahman MT, Nakayama K, Rahman M, Katagiri H, Katagiri A, Ishibashi T, Ishikawa M, Iida K, Nakayama N, Otsuki Y, Nakayama S and Miyazaki K (2012) Fatty acid synthase expression associated with NAC1 is a potential therapeutic target in ovarian clear cell carcinomas. *Br J Cancer* 107: 300-307.
- 10) Stogios PJ, Downs GS, Jauhal JJ, Nandra SK and Privé GG (2005) Sequence and structural analysis of BTB domain proteins. *Genome Biol* 6: R82.
- 11) Nakayama K, Nakayama N, Davidson B, Sheu JJ, Jinawath N, Santillan A, Salani R, Bistow RE, Morin PJ, Kurman RJ, Wang TL and Shih IeM (2006) A BTB/POZ protein, NAC-1, is related to tumor recurrence and is essential for tumor growth and survival. *Proc Natl Acad Sci USA* 103: 18739-18744.
- 12) Ishibashi M, Nakayama K, Yeasmin S, Katagiri A, Iida K, Nakayama N, Fukumoto M and Miyazaki K (2008) A BTB/POZ gene, NAC-1, a tumor recurrence-associated gene, as a potential target for Taxol resistance in ovarian cancer. *Clin Cancer Res* 14: 3149-3155.
- 13) Nakayama K, Rahman MT, Rahman M, Yeasmin S, Ishikawa M, Katagiri A, Iida K, Nakayama N and Miyazaki K (2010) Biological role and prognostic significance of NAC1 in ovarian cancer. *Gynecol Oncol* 119: 469-478.
- 14) Yeasmin S, Nakayama K, Ishibashi M, Katagiri A, Iida K, Purwana IN, Nakayama N and Miyazaki K (2008) Expression of the bric-a-brac tramtrack broad complex protein NAC-1 in cervical carcinomas seems to correlate with poorer prognosis. *Clin Cancer Res* 14: 1686-1691.
- 15) Yeasmin S, Nakayama K, Rahman MT, Rahman M, Ishikawa M, Katagiri A, Iida K, Nakayama N, Otsuki Y, Kobayashi H, Nakayama S and Miyazaki K (2012) Biological and clinical significance of NAC1 expression in cervical carcinomas: a comparative study between squamous cell carcinomas and adenocarcinomas/adenosquamous carcinomas. *Hum Pathol* 43: 506-519.
- 16) Sobin LH, Gospodarowicz MK and Wittekind C (2009) TNM Classification of malignant tumours, 7th ed. pp22-29, Wiley Blackwell, New York.
- 17) Okazaki K, Nakayama N, Nariai Y, Nakayama K, Miyazaki K, Maruyama R, Kato H, Kosugi S, Urano T and Sakashita G (2012) Nuclear localization signal in a cancer-related transcriptional regulator protein NAC1. *Carcinogenesis* 33: 1854-1862.
- 18) Ishibashi M, Nakayama K, Yeasmin S, Katagiri A, Iida K, Nakayama N and Miyazaki K (2009) Expression of a BTB/POZ protein, NAC1, is es-

- sential for the proliferation of normal cyclic endometrial glandular cells and is up-regulated by estrogen. *Clin Cancer Res* 15: 804-811.
- 19) Winning TA and Townsend GC (2000) Oral mucosal embryology and histology. *Clin Dermatol* 18: 499-511.
 - 20) Jones KB and Klein OD (2013) Oral epithelial stem cells in tissue maintenance and disease: the first steps in a long journey. *Int J Oral Science* 5: 121-129.
 - 21) Dale BA, Salonen J and Jones AH (1990) New approach and concepts in the study of differentiation of oral epithelia. *Clit Rev Oral Biol Med* 1: 167-190.
 - 22) Fuchs E (1995) Keratins and the skin. *Ann Rev Cell Dev Biol* 11: 123-153.
 - 23) Squier CA and Kremer MJ (2011) Biology of oral mucosa and esophagus. *J Natl Cancer Monogr* 29: 7-15.
 - 24) Kim J, Chu J, Shen X, Wang J and Orkin SH (2008) An extended transcriptional network for pluripotency of embryonic stem cells. *Cell* 132: 1049-1061.
 - 25) Wang J, Rao S, Chu J, Shen X, Levasseur DN, Theunissen TW and Orkin SH (2006) A protein interaction network for pluripotency of embryonic cells. *Nature* 444: 364-368.
 - 26) Arnold K, Sarkar A, Yram MA, Polo JM, Bronson R, Sengupta S, Seandel M, Geijisen N and Hochedlinger K (2011) Sox2+ adult stem and progenitor cells are important for tissue regeneration and survival of mice. *Cell Stem Cell* 9: 317-329.
 - 27) Sekine J, Uehara M, Hideshima K, Irie A and Inokuchi T (2003) Predictability of lymph node metastases by preoperative nuclear morphometry in squamous cell carcinoma in the tongue. *Cancer Detec Prev* 27: 427-433.
 - 28) Nakayama K, Nakayama N, Davidson B, Katabuchi H, Kurman RJ, Velculescu VE, Shih leM and Wang TL (2006) Homozygous deletion of MKK4 in ovarian serous carcinoma. *Cancer Biol Ther* 5: 630-634.
 - 29) El Hallani S, Poh CF, Macaulay CE, Follen M, Guillaud M and Lane P (2013) Ex vivo confocal imaging with contrast agents for the detection of oral potentially malignant lesions. *Oral Oncol* 49: 582-590.
 - 30) van Zyl AW, van Heerden MB, Langenegger E and van Heerden WF (2012) Correlation between dysplasia and ploidy status in oral leukoplakia. *Head and Neck Pathol* 6: 322-327.
 - 31) Dost E, Lê Cao K, Ford PJ, Ades C and Farah CS (2014) Malignant transformation of oral epithelial dysplasia: a real-world evaluation of histopathologic grading. *Oral Surg Oral Med Oral Pathol Oral Radiol* 117: 343-352.
 - 32) Balasundaram I, Payne KF, Al-Hadad I, Alibhai M, Thomas S and Bhandari R (2014) Is there any benefit in surgery for potentially malignant disorders of the oral cavity? *J Oral Pathol Med* 43: 239-244.
 - 33) Mishra M, Chandavaekar V, Naik VV and Kale AD (2013) An immunohistological study of basement membrane heparin sulfate proteoglycan (perlecan) in oral epithelial dysplasia and squamous cell carcinoma. *J Oral Maxillofac Pathol* 17: 31-35.
 - 34) Davidson B, Berner A, Trope CG, Wang TL and Shih leM (2007) Expression and clinical role of the bric-a-brac tramtrack broad complex/poxvirus and zinc protein NAC-1 in ovarian carcinoma effusions. *Hum Pathol* 38: 1030-1036.
 - 35) Zhang Y, Cheng Y, Ren X, Zhang L, Yap KL, Wu H, Patel R, Liu D, Qin ZH, Shih IM and Yang JM (2012) NAC1 modulates sensitivity of ovarian cancer cells to cisplatin by altering the HMGB1-mediated autophagic response. *Oncogene* 31: 1055-1064.
 - 36) Nishi T, Maruyama R, Urano T, Nakayama N, Kawabata Y, Yano S, Yoshida M, Nakayama K, Miyazaki K, Takenaga K, Tanaka T and Tajima Y (2012) Low expression of nucleus accumbens-associated protein 1 predicts poor prognosis for patients with pancreatic ductal adenocarcinoma. *Pathol Int* 62: 802-810.