

# 学位論文の要旨

氏名 勝部 敬

学位論文名 Estimation of Liver Function Using T1 Mapping on  
Gd-EOB-DTPA-Enhanced Magnetic Resonance Imaging  
発表雑誌名 Investigative Radiology  
(巻: 初頁～終頁等, 年) (46: 277-283, 2011)  
著者名 Takashi Katsube, Masahiro Okada, Seishi Kumano,  
Masatoshi Hori, Izumi Imaoka, Kazunari Ishii,  
Masatoshi Kudo, Hajime Kitagaki, Takamichi Murakami.

## 論文内容の要旨

### INTRODUCTION

Gadolinium ethoxybenzyl diethylenetriamine pentaacetic acid (Gd-EOB-DTPA) has recently come into use in routine clinical practice as a magnetic resonance (MR) contrast agent for T1-weighted images in many countries. Gd-EOB-DTPA is gradually taken up by hepatocytes and eventually excreted via the biliary pathway without any change to the chemical structure. Gd-EOB-DTPA is used to evaluate focal liver lesions, such as hepatocellular carcinoma or liver metastasis on T1-weighted imaging. However, as signal intensity of the liver parenchyma after Gd-EOB-DTPA administration depends on uptake by hepatocytes and bile excretion, Gd-EOB-DTPA is expected to be useful in imaging to evaluate liver function, as well as to evaluate focal liver lesions.

The purpose of this study was to investigate whether Gd-EOB-DTPA-enhanced MR imaging can evaluate liver function using the T1 relaxation time of liver parenchyma.

### MATERIALS AND METHODS

Patients with suspected focal liver lesions in normal liver parenchyma were classified into a normal liver function (NLF) group (n = 16). Patients with chronic hepatitis (CH) were classified into a CH group (n = 38). Patients with liver cirrhosis (n = 37) were classified into 2 groups according to Child-Pugh classification: a liver cirrhosis with Child-Pugh A (LCA) group (n = 20); and a liver cirrhosis with Child-Pugh B (LCB) group (n = 17). No patients showed liver cirrhosis with Child-Pugh C.

All study cases were performed on a clinically available 3-T system. For all patients, Look-Locker sequences (single slice multiphase imaging using gradient-echo sequence with

inversion recovery pulse: repetition time, 12 milliseconds; echo time, 1.7 milliseconds; flip angle, 7°; field of view, 420×285 mm; matrix, 112×66, 256 zip; thickness, 10 mm; acquisition time, 1 phase = 145 ms, 31 phases; acceleration factor, 2) were obtained before and at 3, 8, 13, and 18 minutes after Gd-EOB-DTPA administration. The sequence was obtained as only 1 axial slice at the level of the porta hepatis.

All patients received 0.025 mmol/kg body weight of Gd-EOB-DTPA administered at 2 mL/s through an intravenous line.

The Philips Research Integrated Development Environment (PRIDE) T1 fitting tool was employed for measurement of T1 relaxation time using data from the Look-Locker sequence. PRIDE software can depict T1 relaxation time on a pixel-by-pixel basis in a color distribution map (T1 mapping). For T1 relaxation time assessment of the liver, a region of interest (ROI) was drawn manually in the liver on T1 mapping images obtained before and at 3, 8, 13, and 18 minutes after Gd-EOB-DTPA administration. Five ROIs were sparsely placed in both lobes of liver parenchyma. Mean T1 relaxation time for the 5 ROIs were considered as the representative T1 relaxation time for the liver. In addition, the reduction rate of T1 relaxation time between pre- and postcontrast enhancement at each time was calculated using the following definition:

$$\text{Reduction rate (\%)} = [(T1_{\text{pre}} - T1_{\text{post}}) / T1_{\text{pre}}] \times 100$$

where  $T1_{\text{pre}}$  is the T1 relaxation time before Gd-EOB-DTPA administration and  $T1_{\text{post}}$  is the T1 relaxation time after Gd-EOBDTPA administration.

The Bonferroni *t* test was used to compare the 4 groups for T1 relaxation time of the liver before and after Gd-EOB-DTPA administration and reduction rate of T1 relaxation time in the liver. We used an adjusted *P* value and an adjusted *P* value less than 0.05 was considered to indicate a significant difference in all statistical tests.

## **RESULTS**

Precontrast T1 relaxation time of the liver showed significant differences between NLF and liver cirrhosis groups LCA and LCB (NLF-LCA,  $P = 0.023$ ; NLF-LCB,  $P < 0.001$ ), and between CH and LCB ( $P = 0.001$ ). T1 relaxation times of liver cirrhosis groups LCA and LCB were significantly prolonged in comparison with that of NLF, and that of LCB was significantly prolonged in comparison with that of CH. In terms of postcontrast T1 relaxation time, T1 relaxation times were significantly prolonged for LCB in comparison with other groups at 3, 8, 13, and 18 minutes (NLF-LCB,  $P < 0.001$  at all time points; CH-LCB,  $P < 0.001$  at all time points; LCA-LCB,  $P = 0.004$  at 3 minutes,  $P < 0.001$  at  $\geq 8$  minutes), and T1 relaxation times were significantly prolonged for LCA in comparison with those for NLF at 3, 8, 13, and 18 minutes ( $P = 0.043, 0.003, 0.003, \text{ and } 0.006$ , respectively).

At 3 minutes after Gd-EOB-DTPA administration, reduction rates of T1 relaxation time were significantly lower for LCB than for NLF or CH (NLF-LCB,  $P = 0.014$ ; CH-LCB,  $P =$

0.008), and at  $\geq 8$  minutes, rates were significantly lower for LCB than for all other groups (NLF-LCB,  $P < 0.001$  at  $\geq 8$  minutes; CH-LCB,  $P < 0.001$  at  $\geq 8$  minutes; LCA-LCB,  $P = 0.001$  at 8 minutes,  $P < 0.001$  at  $\geq 13$  minutes). NLF, CH, and LCA showed no significant differences.

## **DISCUSSION**

Precontrast T1 relaxation times in liver cirrhosis groups LCA and LCB were prolonged compared with NLF. Prolonged T1 relaxation time in liver cirrhosis has been reported previously, and prolonged T1 relaxation time without contrast media may suggest liver cirrhosis. However, no correlation was found between the degree of fibrosis and T1 relaxation time, and prolonged T1 relaxation time is not specific to liver cirrhosis. Postcontrast T1 relaxation times were significantly longer for LCB than for other groups at any time point. Also, times for LCA were longer than those for NLF. Postcontrast T1 relaxation time may enable us to distinguish liver cirrhosis from normal liver and to evaluate degree of liver cirrhosis, given the significant difference between LCA and LCB. However, shortening of the postcontrast T1 relaxation time for NLF and prolonged postcontrast T1 relaxation time in LCA and LCB liver cirrhosis may be affected by precontrast T1 relaxation time. We therefore calculated the reduction rate of T1 relaxation time to evaluate the degree of Gd-EOB-DTPA uptake in liver parenchyma. Reduction rate of T1 relaxation times were significantly lower in LCB than in other groups.

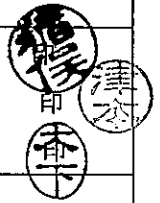
Child-Pugh classification has been reported as a significant prognostic factor after therapies of partial hepatic resection, radiofrequency ablation, percutaneous ethanol injection therapy and transarterial chemoembolization, and the survival rate after these therapies is shorter for Child-Pugh B patients than for Child-Pugh A patients. Child-Pugh classification is one of the most generally used parameters to evaluate reserve liver function. Evaluation of hepatic uptake of Gd-EOB-DTPA, which showed a significant correlation to Child-Pugh classification, may be applicable to estimate liver function. Imaging modalities such as T1 mapping used in this study enable the evaluation of not only whole liver function, but also regional liver function, and may be applied to estimate safe segmental hepatic resection volume and evaluate liver function before and after focal radiofrequency ablation, percutaneous ethanol injection therapy, or transarterial chemoembolization. When liver function is inhomogeneous, Child-Pugh classification or ICG test may be occasionally inadequate for estimating residual liver function after a partial hepatectomy. On the other hand, T1 mapping can be more accurate for estimation of residual liver function, because the technique can evaluate regional liver function.

## **CONCLUSION**

T1 mapping calculated with the Look-Locker sequence appears very useful for measuring signal intensity in liver parenchyma, and evaluation of hepatic uptake of Gd-EOB-DTPA using T1 mapping can help estimate liver function.

論文審査及び最終試験又は学力の確認の結果の要旨

|          |  |       |
|----------|--|-------|
| 甲・乙      | 氏名   | 勝部 敬  |
| 学位論文名    | Estimation of Liver Function Using T1 Mapping on Gd-EOB-DTPA-Enhanced Magnetic Resonance Imaging |       |
| 学位論文審査委員 | 主査   | 猪俣 泰典 |
|          | 副査   | 津本 周作 |
|          | 副査   | 木下 芳一 |



論文審査の結果の要旨

Gadolinium ethoxybenzyl diethylenetriamine pentaacetic acid (Gd-EOB-DTPA)は肝細胞癌や転移性肝腫瘍等の限局した病巣の評価に用いられているMR造影剤のひとつである。本研究ではGd-EOB-DTPAが特異的に肝細胞に取り込まれて代謝されることなく胆汁中に排泄されることに着目してGd-EOB-DTPA投与後に生ずる肝実質のT1緩和時間(T1値)の変化を肝機能の評価にも応用することが可能か否かを3-Tesla MRI撮像装置とLook-Locker sequencesを用いて検討し、以下の結果を得た。

- ① 造影前のT1値は正常機能肝(NFL)群と比較して肝硬変(Child-Pugh A(LCA), Child-Pugh B(LCB))群で有意に延長し、同様にLCB群では慢性肝炎(CH)群よりも、LCA群ではNFL群よりもそれぞれ有意に延長した。
- ② 造影後ではLCB群のT1値は他の3群と比較して有意に延長し、同様にLCA群のT1値はNFL群と比較して有意に延長した。
- ③ Gd-EOB-DTPA投与後3分ではT1値の短縮率はLCB群がNFL群/CH群よりも有意に低く、投与後8分以降では同様にLCB群が他の3群よりも有意に低かった。NFL群、CH群、LCA群間には有意差は認めなかった。
- ④ Accuracy値からは造影18分後がLCB群と他の3群とを区別するのに最適であった。

以上より、本研究で行われたT1 mappingによる画像診断は全肝機能のみではなく部分肝機能評価が定量的に可能であり、より安全な肝切除量の予測やRFA、PEIT、TACE、放射線治療前後での局所肝機能評価をするに当たって有用な情報を提供出来る意義のあるものと判断される。

最終試験又は学力の確認の結果の要旨

申請者は、Gd-EOB-DTPA投与後に見られる肝実質のT1値の変化を肝機能評価に用いることが出来ることに着目し、全肝機能のみではなく部分肝機能評価が定量的に可能であることを証明した。公開審査における質疑応答も的確で背景、関連する分野の知識も充分であり、学位授与に値すると判断した。  
(主査：猪俣 泰典)

申請者らは、Gd-EOB-DTPA投与後のT1値の時間的变化を用いて、血液生化学検査よりも鋭敏な肝機能の定量的評価の枠組みを設計、計測データにより有効性を評価するとともに、肝機能の視覚的な観測を可能とした。関連知識も豊富であり、学位授与に値すると判断した。(副査：津本 周作)

申請者は肝臓の代謝機能とT1 mappingで評価したGd-EOB-DTPAの肝臓への取り込みに明確な関連性があり、Gd-EOB-DTPA MRI が肝機能の評価に有用であることを示した。今後の区域別肝機能の評価方法の確立につながる成果であると考えられる。関連領域の知識も十分であり、博士の学位に値すると判断した。  
(副査：木下 芳一)

(備考) 要旨は、それぞれ400字程度とする。